

ROMANIAN ACADEMY

STOMATOLOGY EDU JOURNAL

since 2014

2022 VOLUME 9 ISSUE 3-4

stomatedu.j

A WORLD OF EDUCATIONAL RESOURCES FOR EACH PRACTICE



PUBLISHING HOUSE
OF THE ROMANIAN ACADEMY

FOUNDING EDITORS:

Jean-François Roulet, USA

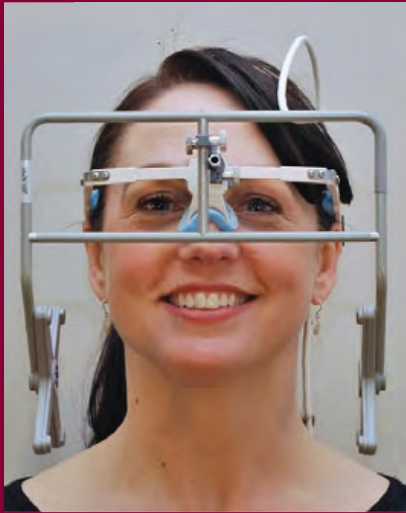
Rolf Ewers, Austria

Marian-Vladimir Constantinescu, Romania

3-4
2022


CE PROGRAM FAQs

Neuromuscular Dentistry *Powered by Myotronics*



Dentists worldwide are discovering the science and the benefits of Neuromuscular Dentistry with Myotronics technology.

Evaluate and successfully treat occlusal and restorative cases with reliable, reproducible clinical data never seen before.

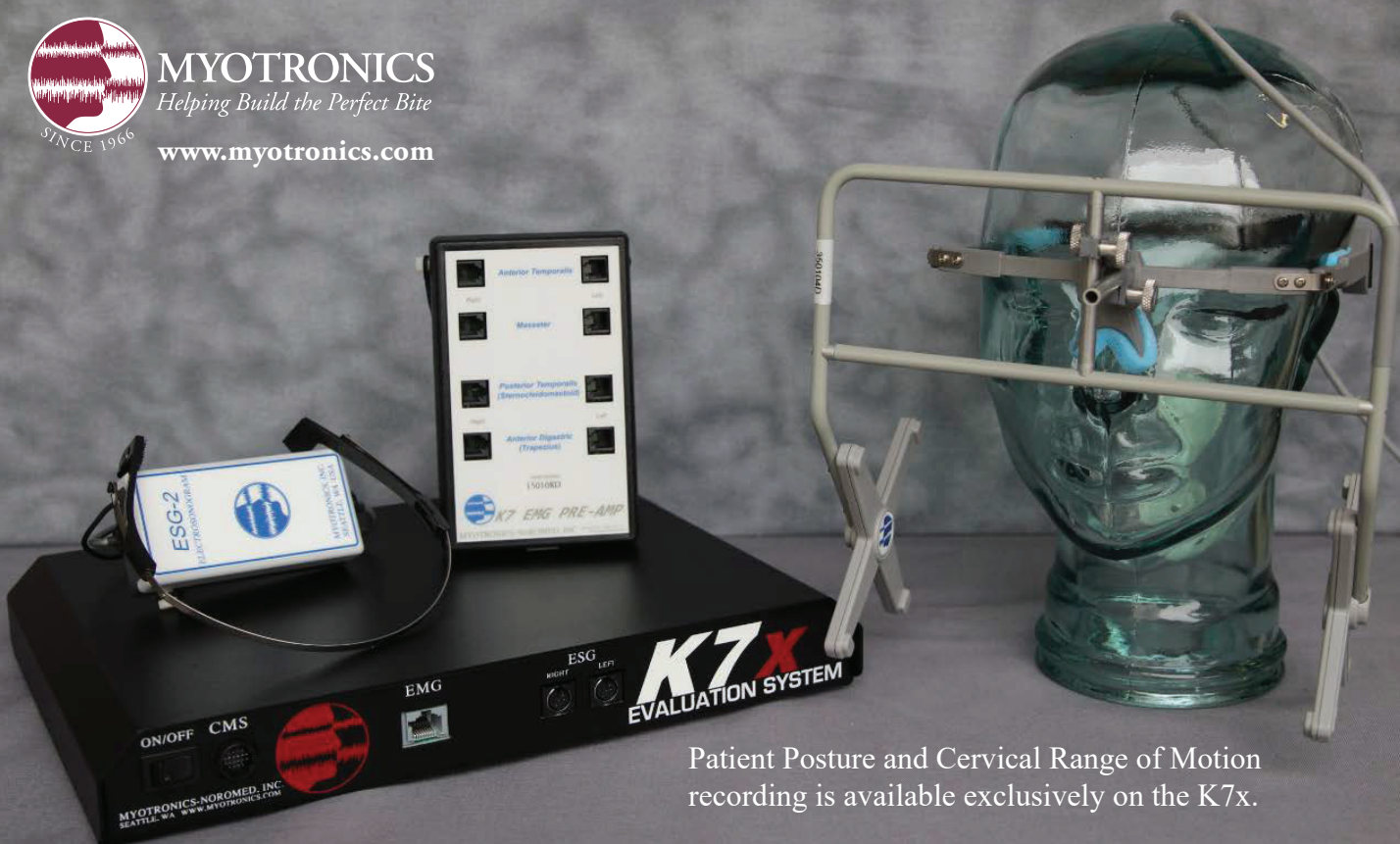

Contact Myotronics to receive information on upcoming CE courses and complimentary booklets on the benefits of Neuromuscular Dentistry.
800.426.0316 or info@myotronics.com.



MYOTRONICS
Helping Build the Perfect Bite

www.myotronics.com



Patient Posture and Cervical Range of Motion recording is available exclusively on the K7x.

More and more dentists worldwide admit:

I

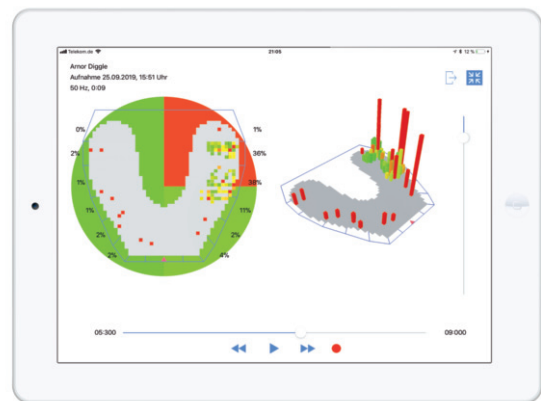


OccluSense®

Innovative device for digital occlusion control.

Take advantage of the award-winning OccluSense® system:

- 60 microns thin, flexible pressure sensors record both static and dynamic occlusion
- Data transfer to OccluSense®-iPad-App via wireless network
- Ergonomic design for intuitive handling
- Additionally, red colour coating marks the occlusal contacts on the patient's teeth



OccluSense®
by Bausch

WE MAKE OCCLUSION VISIBLE®

Dr. Jean Bausch GmbH & Co. KG | Oskar-Schindler-Str. 4 | 50769 Köln | Germany
Tel.: +49-221-709360 | Fax: +49-221-70936-66 | info@occlusense.com | www.occlusense.com
Bausch and OccluSense are trademarks of Dr. Jean Bausch GmbH & Co. KG, registered in Germany and other countries.
Apple and iPad are trademarks of Apple Inc., registered in the U.S. and other countries.

More information:
www.occlusense.com
and YouTube



Supported by:




on the basis of a decision
by the German Bundestag

2022
Volume 9
Issue 3-4
Pages 75-138

GUEST EDITORIAL


75 Nomen est omen - the difficult scientific classification of materials
 Jean-François Roulet

 [https://doi.org/10.25241/stomaedu.2022.9\(3-4\).edit.1](https://doi.org/10.25241/stomaedu.2022.9(3-4).edit.1)



IN MEMORIAM

77 Pages of history - Professor Lucian Ene - a teacher, doctor and scientist
 Paula Perlea, Marian V. Constantinescu

 [https://doi.org/10.25241/stomaedu.2022.9\(3-4\).letter](https://doi.org/10.25241/stomaedu.2022.9(3-4).letter)



CONTINUING EDUCATION ONLINE


79 JADA CE Online




ORIGINAL ARTICLES

81 **POSTUROLOGY:** Effects of masticatory movements on head, trunk and body sway during standing position

Kiwamu Sakaguchi, Keiko Shima, Noshir R. Mehta, Tomoaki Maruyama, Leopoldo P. Correa, Atsuro Yokoyama

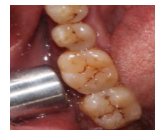 [https://doi.org/10.25241/stomaedu.2022.9\(3-4\).art.1](https://doi.org/10.25241/stomaedu.2022.9(3-4).art.1)



88 **PERIODONTOLOGY:** Low-Level Laser Periodontal Therapy in Diabetic Patients: A Randomized Controlled Clinical Trial - Pilot Study


Fares Al Hajeb, Hala Zakaria, Jovita D'Souza, Wael Hamsho, Omar Al Jadaan, Jumma Al Khabuli


 [https://doi.org/10.25241/stomaedu.2022.9\(3-4\).art.2](https://doi.org/10.25241/stomaedu.2022.9(3-4).art.2)



95 **ORTHODONTICS:** Mandibular incisor inclination in patients with Class II malocclusion: Comparison of treatment effects through time


Anastasia Tsolaki, Maria Tsami, Athina Chatzigianni, Moschos Papadopoulos

 [https://doi.org/10.25241/stomaedu.2022.9\(3-4\).art.3](https://doi.org/10.25241/stomaedu.2022.9(3-4).art.3)




103 **GERODONTOLOGY:** Oral rehabilitation and quality of life in psychiatric patients undergoing deinstitutionalization

Ana María Morasso, María Lujan Pérez Meyer, Sergio Thefs, Luciana D'Eramo, Noemí Bordoni, Aldo Fabián Squassi


 [https://doi.org/10.25241/stomaedu.2022.9\(3-4\).art.4](https://doi.org/10.25241/stomaedu.2022.9(3-4).art.4)

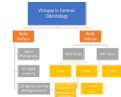	n	DMFT ± SD	D	M	F
Male	66	18.28 (5.56)	2.07	15.48	0.79
Female	97	17.99 (5.56)	1.73	19.22	1.06
Total	163	19.71 (5.54)	1.87	17.52	0.92

REVIEW ARTICLE


- 109** **ORAL MEDICINE:** The oral effects of e-cigarettes – a literature reviews
Áron Imre Györkös, Norbert Kulcsár, Péter Hermann, Barbara Kispélyi
 [https://doi.org/10.25241/stomaedu.2022.9\(3-4\).art.5](https://doi.org/10.25241/stomaedu.2022.9(3-4).art.5)

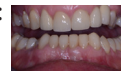

- 115** **FORENSIC ODONTOLOGY:** Virtopsy: A new developing science in forensic odontology
Rashmi GS Phulari, Bharvi Solanki, Dharmesh Vasavada
 [https://doi.org/10.25241/stomaedu.2022.9\(3-4\).art.6](https://doi.org/10.25241/stomaedu.2022.9(3-4).art.6)




CASE REPORT

- 121** **ORAL REHABILITATION :** How to manage the lack of space in an anterior reconstruction: increase the occlusal vertical dimension or reduce periodontal support?
Jean-Philippe Ré, Jean-Daniel Orthlieb, Anne Giraudeau, Estelle Casazza
 [https://doi.org/10.25241/stomaedu.2022.9\(3-4\).art.7](https://doi.org/10.25241/stomaedu.2022.9(3-4).art.7)



PRODUCT NEWS

- 127** The Magdent-MED device ensures an increase in the healing rate of dental implant procedures
Florin-Eugen Constantinescu
 [https://doi.org/10.25241/stomaedu.2022.9\(3-4\).prodnews.1](https://doi.org/10.25241/stomaedu.2022.9(3-4).prodnews.1)



BOOKS REVIEW

- 129** Books review



INSTRUCTIONS FOR AUTHORS

- 136** Instructions for authors



SUBSCRIPTION

- 138** Subscription



EDITORS-IN-CHIEF



Marco Ferrari
 MD, DMD, DDS, PhD, FADM, Professor, Chairperson, Dean
 University of Siena, Siena, Italy



Constantinus Politis
 MD, DDS, MM, MHA, PhD, Full Professor and Chairperson
 University of Leuven, Leuven, Belgium



Marian-Vladimir Constantinescu
 DDS, MSc, PhD, Professor
 "Carol Davila" University of Medicine and Pharmacy, Bucharest, Romania

CO-EDITORS-IN-CHIEF (AMERICAS)



James Richard Hupp
 BS, DMD, MD, JD, MBA, Professor
 Washington State University, Spokane, WA, USA



Hom-Lay Wang
 DDS, MSD, PhD, Professor
 University of Michigan, Ann Arbor, MI, USA



Mauro Marincola
 MD, DDS, Clinical Professor
 State University of Cartagena, Cartagena, Colombia



George E. Romanos
 DDS, PhD, DMD, Professor
 Stony Brook University, Stony Brook, NY, USA

CO-EDITORS-IN-CHIEF (ASIA-PACIFIC)



Lakshman Perera Samaranayake
 Hon DSc, FDSRCS (Edin), FDS RCPS (Glas), FRACDS, FRCPath (UK), BDS, DDS
 (Glas), FHKCPATH, FCDSSHK, FHKAM (Pathology), FHKAM (Dental Surgery)
 Emeritus Professor, Department of Oral Biosciences, Faculty of Dentistry
 Immediate-past Dean, University of Hong Kong, Hong Kong



Hiroshi Ogawa
 DDS, MDSc, PhD, Associate Professor
 Niigata University, Niigata, Japan



Mahesh Verma
 BDS, MDS, MBA, FAMS, FDSRCS (England), FDSRCPG (Glasgow), FDSRCS
 (Edinburgh) PhD (HC), Professor
 Maulana Azad Institute of Dental Sciences, New Delhi, India



Yongsheng Zhou
 DDS, PhD, Professor and Chair, Associate Dean
 Department of Prosthodontics, School of Stomatology (PKUSS), Peking
 University, Beijing, P.R.China

EMERITUS EDITORS-IN-CHIEF



Peter E. Dawson
 DDS, Founder Emeritus of The Dawson Academy
 Saint Petersburg, FL, USA



Adi A. Garfunkel
 DMD, PhD, Professor Emeritus
 Hadassah Hebrew University, Jerusalem, Israel



Robert Louis Ibsen
 DDS, OD, FAGD, FACD, FICD
 Founder & President DenMat Corporation, Santa Maria, CA, USA



Birte Melsen
 DDS, Dr Odont, Professor
 Aarhus University, Aarhus, Denmark



Alexandre Mersel
 DDS, PhD, Professor, Director of Studies
 Geneva Institute of Medical Dentistry (GIMD), Versoix, Switzerland

SECTIONS EDITORS

Joseph Nissan, DMD, Editor-in-Chief
Paula Perlea, DDS, PhD, Co-Editor-in-Chief

Basic Research / Dental Materials / Dental Technology
Gottfried Schmalz, DDS, PhD, Dr hc, Acad (Leopoldina),
 University of Regensburg, Regensburg, Germany -
 Editor-in-Chief
Vasile Iulian Antoniac, Eng, PhD, Habil, Vice Dean,
 University "Politehnica" of Bucharest, Bucharest, Romania
Bogdan Calenic, DDS, PhD, "Carol Davila" University of
 Medicine and Pharmacy Bucharest, Bucharest, Romania
Horia Octavian Manolea, DMD, PhD, Head, University
 of Medicine and Pharmacy of Craiova, Dolj, Romania
Annalisa Monaco, DDS, MSc, PhD, University of L'Aquila,
 L'Aquila, Italy

**Clinical Research / Oral and Dental Diagnosis / Dental
 Radiology / Evidence-Based Dentistry**
Sorin Uram-Țuculescu, DDS, PhD, Virginia Commonwealth
 University, Richmond, VA, USA - Editor-in-Chief
Amid I. Ismail, BDS, MPH, MBA, Dr PH, Dean, Temple
 University, Philadelphia, PA, USA
Fawad Javed, BDS, PhD, University of Rochester, NY, USA
Dalia Kaisarly, BDS, MDS, PhD, University of Munich,
 Munich, Germany
Chiarella Sforza, MD, PhD, University of Milan, Milan, Italy

**Community Dentistry / Oral Epidemiology / Oral Health /
 Dental Public Health / Health Promotion**
Poul Erik Petersen, DDS, Dr Odont, BA, MSc,
 WHO Senior Consultant, University of Copenhagen,
 Copenhagen, Denmark - Editor-in-Chief
Noemi Bordoni, DDS, PhD, Director, Public Health
 Research Institute, Buenos Aires, Argentina
Simona Stoleriu, DMD, PhD, "Gr. T. Popa" University of
 Medicine and Pharmacy Iași, Iași, Romania

Mihnea Ioan Nicolescu, DMD, MD, PhD, "Carol Davila"
 University of Medicine and Pharmacy Bucharest,
 Bucharest, Romania
Mihaela Răescu, DDS, PhD, "Titu Maiorescu" University,
 Bucharest, Romania

Cariology / Pedodontics / Oro-Dental Prevention
Luca Levrini, DDS, PhD, University of Insubria, Varese,
 Italy - Editor-in-Chief
Sorin Andrian, DDS, PhD, "Gr. T. Popa" University of
 Medicine and Pharmacy Iași, Iași, Romania
Dana Cristina Bodnar, DDS, PhD, "Carol Davila"
 University of Medicine and Pharmacy Bucharest,
 Bucharest, Romania
Iulia Georgievna Romanova, DMS, PhD, Odessa
 National Medical University, Odessa, Ukraine
Tamara Tserakhava, DDS, PhD, Belarusian State
 Medical University, Minsk, Belarus

DEPUTY EDITORS-IN-CHIEF

Adrian Bejan
 Eng, PhD, J.A. Jones Distinguished Professor, Acad (AR)
 Duke University, Durham, NC, USA



Constantin Ionescu-Târgoviste
 MD, PhD, Professor, Acad (AR)
 "Carol Davila" University of Medicine and Pharmacy, Bucharest, Romania



Gabriel Octavian Lazăr
 Phys, PhD, Professor
 "Vasile Alecsandri" University of Bacău, Bacău, România



CO-EDITORS-IN-CHIEF (EUROPE)

Gavriel Chaushu
 DMD, MSc, Professor, Head
 Rabin Medical Center, Beilinson Campus, Petah Tikva, Israel
 The Maurice and Gabriela Goldschleger School of Dental Medicine
 Tel Aviv University, Tel Aviv, Israel



Mutlu Özcan
 DDS, PhD, Professor, Head Division of Dental Biomaterials
 Clinic of Reconstructive Dentistry, Center of Dental Medicine (ZZM)
 University of Zürich, Zürich, Switzerland



Letizia Perillo
 MD, MS, PhD, Professor
 Head, Dean, University of Campania Luigi Vanvitelli, Naples, Italy



Hande Şar Sancaklı
 DDS, PhD, Associate Professor
 FDI Regional CE Director Europe, Geneva-Cointrin, Switzerland



SENIOR EDITORS

Bruce Robert Donoff
 DMD, MD, Professor, Dean
 Medicine Harvard University, Boston, MA, USA



Rolf Ewers
 MD, DMD, PhD Professor and Chairman em.
 Medical University of Vienna, Vienna, Austria



Adrian Podoleanu
 Eng, PhD, Professor, FlinstP, FOSA, FSPiE, Professor
 University of Kent, Canterbury, Kent, UK



Saman Warnakulasuriya
 BDS, FDSRCS (Eng), FDSRCS (Edin), FDSRCPG (Glasg), PhD(Glasg)
 DSc, FKC, Professor
 King's College London, London, UK



EMERITUS EDITORS-IN-CHIEF

Prathip Phantumvanit
 DDS, MS, FRCDT, Professor
 Thammasat University, Bangkok, Thailand



Jacques Vanobbergen
 DDS, PhD, Professor Emeritus
 Gent University, Gent, Belgium



Rudolf Slavicek
 MD, DMD, Professor
 Medical University of Vienna, Vienna, Austria



Julian B. WOELFEL
 DDS, FACD, FICD, Professor Emeritus
 College of Dentistry, The Ohio State University, Columbus, Ohio, U.S.A



David Wray
 MD (Honours), BDS, MB ChB, FDS, RCPS (Glasgow), FDS RCS (Edinburgh) F Med
 Sci Professor Emeritus, Professor, University of Glasgow, Glasgow, UK



Minimally Invasive Dentistry / Dental Laser

Akira Aoki, DDS, PhD, Tokyo Medical and Dental University (TMDU), Tokyo, Japan - Editor-in-Chief
Marcus Oliver Ahlers, DDS, PhD, Hamburg University Eppendorf, Hamburg, Germany
Peter Hermann, DMD, MSc, PhD, Head, Vice-Rector, Semmelweis University Budapest, Budapest, Hungary
Sanda-Mihaela Popescu, DDS, MSc, PhD, University of Medicine and Pharmacy of Craiova, Dolj, Romania
Roman Smuder, MD, PhD, Charles University Prague, Prague, Czech Republic

Aesthetic Dentistry / Dental Photography

Douglas A. Terry, DDS, PhD, University of Texas, Houston, TX, USA - Editor-in-Chief
Lucian Toma Ciocan, DMD, PhD, Head, "Carol Davila" University of Medicine and Pharmacy Bucharest, Bucharest, Romania
Daniele Maria Gibelli, MD, PhD, University of Milan, Milan, Italy
Galip Gürel, DDS, MSc, Dentis Dental Clinic, Istanbul, Turkey
Henriette Lerner, DMD, PhD, HL Dentclinic & Academy, Baden-Baden, Germany

Endodontics and Traumatology / Dental Microscopy

Niraj Kinariwala, BDS, MDS, PhD, Karnavati University, Gandhinagar, India - Editor-in-Chief
Arnaldo Castellucci, DDS, PhD, Florence, Italy
Enrico Manca, DDS, PhD, Dental Clinic Dr. Enrico Manca, Cagliari, Italy
Paula Perlea, DDS, PhD, "Carol Davila" University of Medicine and Pharmacy Bucharest, Bucharest, Romania
Zrinka Tarle, DMD, PhD, Dean, University of Zagreb, Zagreb, Croatia

Periodontology / Oral Microbiology / Dental Hygiene

Mariano Alonso Sanz, DDS, MSD, PhD, Complutense University of Madrid, Madrid, Spain - Editor-in-Chief
Gabriela Băncescu, MD, MSc, PhD, "Carol Davila", University of Medicine and Pharmacy Bucharest, Bucharest, Romania
Radmila R. Obradović, DDS, PhD, University of Niš, Niš, Serbia
Alina Pūrienė, BS, PhD, Dr hábil, Vilnius University, Vilnius, Lithuania
Jon Byron Suzuki, DDS, PhD, MBA, Associate Dean, Temple University, Philadelphia, PA, USA

Oral Medicine / Oral Pathology

Mare Saag, DDS, PhD, University of Tartu, Tartu, Estonia - Editor-in-Chief
Asja Celebić, DDS, MSc, PhD, University of Zagreb, Zagreb, Croatia
Valeriu Fala, DM, PhD, MSc, "Nicolae Testemițanu" State University of Medicine and Pharmacy, Chișinău, Republic of Moldova
Maria Greabu, Chem, PhD, Head, "Carol Davila" University of Medicine and Pharmacy Bucharest, Bucharest, Romania
Mei-Qing Wang, DDS, PhD, Air Force Medical University (AFMU), Xi'an, Shaanxi, P.R.China

Occlusion and TMJ / Orofacial Pain / Dental Occlusion and Posture

Noshir R. Mehta, DMD, MDS, MS, Associate Dean, Tufts University, Boston, MA, USA - Editor-in-Chief
Nader Farhan Abdulhameed, BDS, MS, MSc, PhD, LECOM School of Dental Medicine, FL, USA
Rafael Benoliel, DDS, PhD, BDS, Associate Dean, The State University of New Jersey, Newark, NJ, USA
Jean-Daniel Orthlieb, DDS, PhD, Vice-Dean, Aix Marseille University, Marseille, France
Sven Erik Widmalm, DDS, Dr Odont, University of Michigan, Ann Arbor, MI, USA

Orthodontics and Dento-Facial Orthopedics

Moschos A. Papadopoulos, DDS, DMD, Chairman, Aristotle University of Thessaloniki, Thessaloniki, Greece - Editor-in-Chief
Fabrizia d'Apuzzo, DDS, MSc PhD, Research Fellow, University of Campania "Luigi Vanvitelli", Naples, Italy
Stella Chaushu, DMD, PhD, Chair, Hebrew University Hadassah Jerusalem, Jerusalem, Israel
Ecaterina Ionescu, DDS, PhD, Vice-Rector, "Carol Davila" University of Medicine and Pharmacy Bucharest, Bucharest, Romania
Abdolreza Jamilian, DDS, PhD, Tehran University of Medical Sciences, Tehran, Iran

Anesthesiology / Dentoalveolar Surgery / Maxillofacial Surgery / Oral Implantology / Emergencies at the Dentist's

Michael Frank, DDS, PhD, ERO President, German Dental Chamber, Frankfurt am Main, Germany - Editor-in-Chief
Jaafar Abduo, BDS, DclinDent, MRACDS, PhD The University of Melbourne, Victoria, Australia
Cristian Niky Cumpătă, DMD, MD, MSc, PhD, "Titu Maiorescu" University Bucharest, Bucharest, Romania
Joel Motta Junior, DMD, PhD, State University of Londrina, Londrina, Brazil
Giorgio Lombardo, MD, DDS, University of Verona, Verona, Italy

Prosthetic Dentistry / Oral Rehabilitation / Gerodontology

Veronica Mercuț, DMD, PhD, Vice-Rector, University of Medicine and Pharmacy Craiova, Dolj, Romania - Editor-in-Chief
Emilian Hutu, DDS, PhD, "Carol Davila" University of Medicine and Pharmacy Bucharest, Bucharest, Romania
Marina Meleşcanu-Imre, DDS, PhD, "Carol Davila" University of Medicine and Pharmacy Bucharest, Bucharest, Romania
Vjekoslav Jerolimov, DDS, PhD, Acad (CASA), University of Zagreb, Zagreb, Croatia
Anastassia E. Kossioni, DDS, PhD, University of Athens, Athens, Greece

Restorative Dentistry / Computerized Dental Prosthetics

François Duret, DDS, DSO, PhD, MS, MD, PhD, Acad (ANCD), University of Montpellier, Montpellier, France - Editor-in-Chief
Joannis Katsoulis, DMD, PhD, University of Bern, Bern, Switzerland
Georg B. Meyer, DMD, PhD, Dr hc, Chairman, Ernst-Moritz-Arndt University, Greifswald, Germany
Dana Ospanova, DDS, PhD, Astana Medical University, Nur-Sultan, Kazakhstan
Roberto Carlo Spreafico, MD, DMD, Busto-Arsizio, Milan, Italy

EDITORIAL ADVISORY BOARD SECTIONS

Stephen F. Rosenstiel, BDS, MSD, Prof. Em., Editor-in-Chief
Andrei Cristian Ionescu, DDS, PhD, Co-Editor-in-Chief

Basic Research / Dental Materials / Dental Technology

Ralf Janda, Chem, Dr rer nat, Habil, Heinrich-Heine-University Düsseldorf, Düsseldorf, Germany - Editor-in-Chief
Andrei Cristian Ionescu, DDS, PhD, University of Milan, Milan, Italy
Nikolay Ishkitiev, DMD, PhD, Medical University of Sofia, Sofia, Bulgaria

Clinical Research / Oral and Dental Diagnosis / Dental Radiology / Evidence-Based Dentistry

Rodolfo Isaac Miralles Lozano, MD, PhD, University of Chile, Santiago, Chile - Editor-in-Chief
Cristina Teodora Preoteasa, DMD, PhD, "Carol Davila" University of Medicine and Pharmacy Bucharest, Bucharest, Romania
Robert Sabinu Șerban, Eng, PhD, MSc, "Carol Davila" University of Medicine and Pharmacy Bucharest, Bucharest, Romania

Community Dentistry / Oral Epidemiology / Oral Health / Dental Public Health / Health Promotion

Amar Hassan Khamis Mohamed Omer, PhD, DEA, MSc, BSc, Mohammed Bin Rashid University of Medicine and Health Sciences, Dubai, UAE - Editor-in-Chief
Nina Mussurlieva, DDS, PhD, Medical University of Plovdiv, Plovdiv, Bulgaria
Aldo Fabián Squassi, DDS, PhD, Chair, University of Buenos Aires, Buenos Aires, Argentina

Cariology / Pedodontics / Oro-Dental Prevention

Vladimir Margvelashvili, MD, PhD, DMScI, Tbilisi State University, Tbilisi, Georgia - Editor-in-Chief
Dorjan Hysi, DDS, PhD, University of Medicine of Tirana, Tirana, Albania
Rodica Luca, DDS, PhD, "Carol Davila" University of Medicine and Pharmacy Bucharest, Bucharest, Romania

Minimally Invasive Dentistry / Dental Laser

Domenico Massironi, DDS, MEG – Master Educational Group, Melegnano (MI), Italy - Editor-in-Chief
Joanna Kempler, DDS, PhD, University of Maryland, Baltimore, MD, USA
Vygandas Rutkūnas, DDS, PhD, Vilnius University, Vilnius, Lithuania

Aesthetic Dentistry / Dental Photography

Bernard Touati, DDS, PhD, Paris V University, Paris, France - Editor-in-Chief
John C. Kois, DMD, MSD, Kois Center, LLC, Seattle, WA, USA
Joseph Nissan, DMD, Tel Aviv University, Tel Aviv, Israel

Periodontology / Oral Microbiology / Dental Hygiene

Anton Sculean, DMD, MS, Dr hc, University of Bern, Bern, Switzerland - Editor-in-Chief
Mario R. Cappellin, DDS, MBE, Clinica dentale Cappellin srl, Pinerolo (TO), Italy
Marian Neaguț, MD, PhD, Acad (ASM), "Carol Davila", University of Medicine and Pharmacy Bucharest, Bucharest, Romania

Oral Medicine / Oral Pathology

Ingrida Ēma, DDS, PhD, Riga Stradins University, Riga, Latvia - Editor-in-Chief
Romeo Călărășu, MD, PhD, Acad (ASM), "Carol Davila", University of Medicine and Pharmacy Bucharest, Bucharest, Romania
Rashmi GS Phulari, BDS, MDS, Bhavnagar University, Vadodara, India

Occlusion and TMJ / Orofacial Pain / Dental Occlusion and Posture

Gregor Slavicek, DDS, PhD, Steinbeis University Berlin, Berlin, Germany - Editor-in-Chief
Luigi Maria Gallo, PhD, Dr. Ing., MEng, University of Zürich, Zürich, Switzerland
Minh Son Nguyen, DDS, PhD, Head, Danang University of Medical Technology and Pharmacy, Danang, Vietnam

Orthodontics and Dento-Facial Orthopedics

Fabio Savastano, MD, MOrth, Jaume I University, Castellón de la Plana, Castellón, Spain - Editor-in-Chief
Andreu Puigdollers-Pérez, DDS, PhD, International University of Catalunya (UIC), Barcelona, Spain
Irina Nicoleta Zetu, DDS, PhD, "Gr. T. Popa" University of Medicine and Pharmacy Iași, Iași, Romania

Anesthesiology / Dentoalveolar Surgery / Maxillofacial Surgery / Oral Implantology / Emergencies at the Dentist's

Nardi Casap-Caspi, DMD, MD, Hebrew University Hadassah Jerusalem, Jerusalem, Israel - Editor-in-Chief
Andreza Lauria de Moura, DMD, PhD, Federal University of Amazonas (FAO-UFAM), Manaus – AM, Brazil
Gianluca Martino Tartaglia, DDS, PhD, University of Milan, Milan, Italy

Prosthetic Dentistry / Oral Rehabilitation / Gerodontology

Grigorios Polyzois, DDS, Dr. Dent, MScD, National and Kapodistrian University of Athens, Athens, Greece - Editor-in-Chief
Elena Preoteasa, DDS, PhD, "Carol Davila" University of Medicine and Pharmacy Bucharest, Bucharest, Romania
Martina Schmid-Schwab, DDS, PhD, Medical University of Vienna, Vienna, Austria

Restorative Dentistry / Computerized Dental Prosthetics

Stephen F. Rosenstiel, BDS, MSD, Prof. Em., The Ohio State University, Columbus, USA - Editor-in-Chief
Mariam Margvelashvili-Malament, DDS, MSc, PhD, Tufts University, Boston, MA, USA
Alexandru Eugen Petre, DDS, PhD, "Carol Davila" University of Medicine and Pharmacy Bucharest, Bucharest, Romania

ENGLISH LANGUAGE EDITOR-IN-CHIEF

Roxana-Cristina Petcu, Faculty of Foreign Languages, University of Bucharest, Bucharest, Romania

ENGLISH LANGUAGE EDITORS

Valeria Clucerescu, Biol., Bucharest, Romania
Diana Florea, Phil, PhD, Bucharest, Romania

HONORARY STATISTICAL ADVISERS

Radu Burlacu, PhD, Bucharest, Romania
Amar Hassan Khamis Mohamed Omer, PhD, DEA

BOOKS REVIEWERS

Iulia Ciolachi, DMD, Bucharest, Romania
Florin-Eugen Constantinescu, DMD, PhD Student, Bucharest, Romania

JOURNAL MANAGER

Ioana Bălan, Maths, MSc, Bucharest, Romania

PROJECT EDITOR

Irina-Adriana Beuran, DMD, PhD, Bucharest, Romania
Carmen Liliana Defta, Biol, PhD, Bucharest, Romania
Alexandra Popa, Bucharest, Romania

TECHNICAL EDITORS

Gabriel Octavian Lazăr, Bucharest, Romania
Valentin Miroiu, Bucharest, Romania
Edgar Moraru, Bucharest, Romania
Johannes Friedrich Carl Rohr, Riga, Latvia
Mirel Toma, Bucharest, Romania

DTP / GRAPHIC & WEB DESIGNER

Valentin Miroiu, Bucharest, Romania



The *Stomatology Edu Journal* (Stoma Edu J) is a scientific magazine of the Romanian Association of Oral Rehabilitation and Posturotherapy – ROPOSTURO, a partner of the FDI regular member, the Romanian Society of Stomatology – RSS (founded in 1923) under the aegis of The Romanian Academy.

Editor Office

Stomatology Edu Journal, 102-104 Mihai Eminescu st.
2nd District, RO-020082 Bucharest, ROMANIA
Tel/Fax: +40314327930,
e-mail: stomatology.edu@gmail.com
www.stomaeduj.com

Editors-in-Chief

Marco Ferrari, Constantinus Politis
Marian-Vladimir Constantinescu

Managing Editor

Florin-Eugen Constantinescu

ROPOSTURO

Romanian Association of Oral Rehabilitation and Posturotherapy
10, Ionel Perlea St., 1st District
RO-010209 Bucharest, Romania
Tel: +4021 314 1062; Fax: +4021 312 1357
e-mail: roposturo@gmail.com
www.roposturo.ro

Technical Editors

Gabriel Octavian Lăzar
Valentin Miroiu
Edgar Moraru
Mirel Toma

Project Editor

Irina-Adriana Beuran

Design Editor

Ovidiu Zanfir

Cover by

Arch. Florin Adamescu

Publisher Office

Romanian Academy Publishing House
Calea 13 Septembrie, 5th District
RO-050711 Bucharest, Romania
Tel: +40213188146
Fax: +40213182444
e-mail: edacad@ear.ro
www.ear.ro

Technical Editor

Doina Argeşanu

Editorial Assistant

Monica Stanciu

Computer Editing

Iolanda Povară

All the original content published is the sole responsibility of the authors. All the interviewed persons are responsible for their declaration and the advertisers are responsible for the information included in their commercials.

Nomen est omen - the difficult scientific classification of materials



Jean-François ROULET
DDS, Habil, Prof hc, Dr hc, Professor
University of Florida, Gainesville, FL, USA
Stomatology Edu Journal
Founding Editor

Dear readers,

Names are used to identify and classify. Your family name, surname and birthday are together an excellent identifier. I know another dentist named Jean-François Roulet in Brazil; however, his birthday is different. In the modern world, this may be replaced by a number such as the Swiss AHV-number = Army identification number, which is derived from the person's name and birthday, or in the USA the Social Security number [1]. In science, names are used to classify as well. Examples are "mammals" (a warm-blooded vertebrate animal of a class that is distinguished by the possession of hair or fur, the secretion of milk by females for the nourishment of the young, and (typically) the birth of live young), "fish" (a limbless cold-blooded vertebrate animal with gills and fins and living wholly in water), or "metal" (a solid material that is typically hard, shiny, malleable, fusible, and ductile, with good electrical and thermal conductivity). However, names may be used as well to deceive or hide something. Examples are "Deutsche Demokratische Republik", which in reality was a State that had disabled all democratic functions and was governed strictly top-down. Other (current) examples are the fancy term "military operation" instead of "war," and, in dentistry, "Artglass" as a member of the class "Polyglass." "Artglass" was a light/heat cured resin composite produced to veneer metal crowns and fixed dental prostheses. The standard of care at the time was porcelain fused to metal or heat-cured PMMA, the latter having a very bad reputation due to its poor performance. Marketing must have known that it would be difficult to sell a resin-based material to the dental technicians. So, the class "Polyglass" was created with the argumentation that the polymerized resin matrix is amorphous (no crystalline structure), which in chemistry can be named vitroid (= like glass) and the fillers are glass particles; ergo, a lot of dental materials can be named "Polyglass." Thus, the buyer of "Artglass" did not get any hint that he/she was buying a resin composite [2].

Lately, I participated in an annual meeting of a professional association where a Professor used the term "Resin Matrix Ceramics" to refer to a ceramic classification. I personally have a big problem with this term and it made me get back to a dormant project of mine. Why? Because scientists in our research area are following the names and classifications that have been formulated with sales in mind [3].

Let's look at the definitions: composite means made out of various parts. This means that the material is made out of two or more distinct phases. For the resin composite, these are unpolymerized or polymerized resins also labelled as the continuous phase (matrix) and the other phases (fillers) which are usually dispersed in the matrix [5]. Resin composites are not the only composites used in dentistry. For example, some impression materials are usually filled and, thus, comply with the term composite. Dental Ceramics, a ceramic is a manmade hard, brittle, heat-resistant, and corrosion-resistant material made by shaping and then firing an inorganic, nonmetallic material at a high temperature, or simpler nonmetallic inorganic materials produced by firing at a high temperature to achieve desired properties [2]. Dental ceramics are either glass-based with reinforcing crystals (leucite, lithium disilicate) or polycrystalline (Zirconium oxide).

Based on these definitions, a "resin matrix ceramic" is a contradiction per se, since resin is neither inorganic nor heat resistant.

This confusion started when 3M company named their composite CAD-CAM block with a composition very close to their direct resin composite Filtek Supreme, but heat-cured only, Lava Ultimate. Since Lava at the time was 3M's brand name for their ceramic line, the name Lava Ultimate suggests ceramic. In 2015, Gracis et al [3] published a ceramic classification in which they created a category "resin-matrix-ceramics" well knowing that this contradicted the correct definition of ceramic cited above! They described it as "materials with an organic matrix highly filled with ceramic particles." This alone is a scientific sin, because resin composites fit in perfectly in this definition. To make matters worse, they created three subcategories: "resin nanoceramic;" "glassceramic in a resin interpenetrating network;" and "zirconia-silica ceramic in a resin interpenetrating

matrix” - using the companies’ marketing descriptions. Mainjot et al (2016) stated that such blocks are resin composites, but suggested that the resin composite class of CAD-CAM blocks should be divided into two subclassifications depending on their microstructure: “with dispersed fillers” or “with polymer infiltrated ceramic matrix” [4]. In my opinion, the real culprit is the American Dental Association (ADA) which in 2013 changed in the Code on Dental Procedures and Nomenclature (ADA 2013) the definition of ceramic for coding to: “pressed, fired, polished or milled materials containing predominantly inorganic, refractory compounds – including porcelains, glasses, ceramics, and glass-ceramics.” With this, any indirect composite restoration could be classified as a ceramic restoration. The only reason for this, in my opinion, is that it is \$-driven. As a consequence, Lava Ultimate was advertised as “can be coded as ceramic.” It is understandable that many customers thought it is ceramic.

Unfortunately, the academic world followed by creating a big confusion. On July 1st, 2021, I searched the Internet for Lava Ultimate; the query produced 307 hits, out of which 297 were further analyzed. I checked in every paper if Lava Ultimate was used and how the authors characterized or classified it. First, I checked if there was a characterization table, and if there was no table, I read the Introduction and the Materials and Methods sections to see how the material was described. 135 times terms classified it as ceramic, with “resin nanoceramic” being the most frequently used (98x). 131 times classified it as a composite, however, only 23 times the material was correctly named “resin composite” or “composite” (19), not classified, brand name (18x), and “composite resin” (17). After these 4 terms, there were 48 terms that, with lots of benevolence, could be summarized as resin composite. Eight names I found were neither composite nor ceramic. This is a clear indication that the authors did not really know what the material was. Here are just a few examples: resin CAD-CAM blocks, Polymer-based blocks, compact filled composite, multiphase resin composite blocks, nanoparticle polymerized resin composite, multiphase resin CAD-CAM material, etc. The damage done by poorly naming and disclosing the composition of a material is obvious.

Seeking transparency/clarity, I am asking manufacturers to be correct in naming and disclosing what is inside and I am asking my publishing and teaching colleagues not to disseminate the marketing stories and to stick to sound scientific terminology. Lava Ultimate is not a ceramic as well as all the blocks that contain resins, even if the inorganic part is connected as a network or the resin is much better polymerized than the ones in resin composites after direct application. They are all resin composites.

Sincerely yours,

J-F Roulet
Stomatology Edu Journal
Founding Editor

REFERENCES

1. American Dental Association. CDT Code on dental procedures and nomenclature. <http://www.ada.org/en/publications/cdt/>. Denry IL. Restorative materials – Ceramics. In Powers JM, Sakaguchi RL (eds). 2. Craigs Restorative Dental Materials, ed 12. St. Louis: Mosby; 2006: 253-275. [CrossRef](#)
3. Gracis S, Thompson VP, Ferencz JL, et al. A new classification system for all-ceramic and ceramic-like restorative materials. *Int J Prosthodont*. 2015 May-Jun;28(3):227-235. doi: 10.11607/ijp.4244. PMID: 25965634. [Full text links CrossRef PubMed Google Scholar WoS](#)
4. Mainjot AK, Dupont NM, Oudkerk JC, et al. From artisanal to CAD-CAM blocks: state of the art of indirect composites. *J Dent Res*. 2016 May;95(5):487-95. doi:10.1177/0022034516634286. PMID: 26933136. [Full text links CrossRef PubMed Google Scholar WoS](#)
5. Watts DC. Resin composite or composite resin? *Dent Mater*. 2020 Sep;36(9):1115. doi:10.1016/j.dental.2020.07.002. PMID: 32713508 [Full text links CrossRef PubMed](#)

Pages of history: Professor Lucian Ene - a teacher, doctor and scientist

Lucian Ene, a renowned dentist and professor, passed away in October 2022 at the age of 96. He will be deeply missed by his family, friends, colleagues, and patients.

Professor Lucian Ene was born on the 28th of May, 1926 in Balta Doamnei, Ploiești Region and in 1953 graduated from the Faculty of Dental Medicine, which had been established in 1948, being one of the first students of this faculty. Previously, dentistry was a specialisation after studying general medicine. Art. 89 of the 1898 education laws state that "pharmaceutical and dental education" are part of the Faculty of Medicine in Bucharest, regarding "the courses and laboratories, as well as the placements in hospitals and mandatory examinations which must be passed in order to obtain the title of Dentist" [1]. In his first years as a dental student, Professor Lucian Ene developed a love for dentistry. He pursued his passion and became a respected dentist in his community, known for his expertise and compassionate approach to patient care. He graduated as a Valedictorian, being awarded a republican scholarship. He also attended courses at the University in Paris.

In 1952 he became Assistant Professor in Orthopaedic Stomatology and in 1965 Associate Professor Lucian Ene also held a position as full Professor beginning with 1969, where he inspired and mentored countless students over the years. He activated as Dean of the Faculty of Dentistry for 2 years: 1961-1962. His dedication to teaching was evident, as shown by his guiding generations of students into careers in health and social care, social work, policy development and academia [2].

For his activity, Professor Ene was awarded numerous prizes throughout his career.

In 1954 he worked as the head of the Dental Service in the Ministry of Health. In 1956 he embarked upon an important stage in his career as a member of the editorial board of the dental magazine, bringing in new medical knowledge through numerous publications.

In time, Professor Lucian Ene was an active member of various organizations and institutions meant to develop dental care, holding positions such as director of the Dental Hospital no 20 in Bucharest, dean and vice-dean of the Faculty of Dentistry in Bucharest, secretary of the Union of the Scientific Medical Societies (USSM), member of the numerous committees of the Ministry of Health and the Ministry of Education.



From the beginning until late in his career, he participated in health campaigns of a sanitary, epidemic and organizational nature in cities like Bucharest, Baia Mare, Suceava, Banat, Brasov, Cluj.

As a member of the university staff, he benefited from the guidance of the famous Prof. Dr. Eugen Costa, the latter being a permanent guide in his career [2]. In his teaching activity, he took care of the preclinical prosthodontic department. In 1955 he managed to develop a course for dental technicians, sharing his knowledge and experience.

Prof. Dr. Lucian Ene's daily activities were of tremendous importance for his students, such as internships with dental faculty students, internships with the students of the faculty of general medicine and pediatrics.

He co-authored numerous courses in prosthetics like: 'Treatment of total edentulous patient', 'Coronary lesions and their therapy', 'Orthodontics course' [3].

In 1959 he published a valuable book meant for students about practical works in orthopedics and prosthetics, This excellent book, containing theoretical and practical tips for daily practice was sold out in a very short period of time. Even the second edition had a resounding success. Together with Professor Eugen Costa, he also published 'The course on materials and alloys used in dental prosthetics', which, for many years, offered the guidelines in dental material science.

Lucian Ene was a remarkable university professor and a huge personality in the field of dentistry, honorary president of the Romanian Society of Stomatology and former dean of the Faculty of Dentistry within the Bucharest Institute of Medicine and Pharmacy. He supervised PhD theses, he developed a dental school, and in this way he managed to leave his mark on the history of dentistry in Romania. His name is linked to the dental higher education for the last seven decades.

Prof. Dr. Lucian Ene contributed to the development of science alongside important names in Romanian medicine as Eugen Costa, Stelica Dumitrescu, Andrei Ionescu, Emilian Hutu, leaving behind scientific works and publications that helped students and dentists [3,4]:

- 'Impression for total edentation' (1970)
- 'Dental prosthetics – partial and total edentation' (1975)

Paula Perlea, DDS, PhD, Habil, Professor
President of the Romanian Society of Stomatology
Member of the ERO-FDI Board
Co-Editor-in-Chief Stomatology Edu Journal

- 'Lesions of dental crowns and their prosthetic treatment' (1978)
- 'Treatment of partial edentation with the help of removable prostheses' (1981)
- 'Skeletal prostheses' (1982)
- 'Partial edentation treated with removable prostheses' (1989)

Simplicity, involvement in the organization and improvement of the education system will always be respected and remembered. The former students expressed their gratitude by continuing his scientific contributions.

As a training of numerous generations of doctors, Professor Lucian Ene will be remembered for his empathy, selflessness, and lifelong services to medicine.

Professor Lucian Ene impact on the field of dentistry and his caring nature will be forever remembered by those who knew him. He will be greatly missed, but his legacy will live on through the countless lives he touched.

Marian V. Constantinescu, DDS, MSc, PhD, Professor
Secretary General of the Romanian Society
of Stomatology
Editor-in-Chief Stomatology Edu Journal

REFERENCES

1. <https://umfcd.ro/en/education/faculty-of-dentistry/>
2. <https://ro.wikipedia.org/wiki/Categorie:Stomatologi>
3. https://ro.wikipedia.org/wiki/Lucian_Ene
4. https://en.wikipedia.org/wiki/Category:Academic_staff_of_the_Carol_Davila_University_of_Medicine_and_Pharmacy



Stoma Edu J. 2022;9(3-4)79

From The Journal of the American Dental Association



JADA ONLINE CE EXAMS

<http://jada.ada.org/ce/home>

<http://jada.ada.org/ceworksheets>

December 21, 2022

EFFECTIVENESS OF BARRIER DEVICES, HIGH-VOLUME EVACUATORS, AND EXTRAORAL SUCTION DEVICES ON REDUCING DENTAL AEROSOLS FOR THE DENTAL OPERATOR

Wayne David Remington, Brian Chandler Ott, Thomas Ryan Hartka,

J Am Dent Assoc. 2022 April;153(4): 309-318.

Doi: <https://doi.org/10.1016/j.adaj.2021.08.011>

[https://jada.ada.org/article/S0002-8177\(21\)00546-8/fulltext](https://jada.ada.org/article/S0002-8177(21)00546-8/fulltext)

This article has an accompanying online continuing education activity available at:

<https://doi.org/10.1016/j.adaj.2021.08.011>

PMID: 34952683

DOI: <https://doi.org/10.1016/j.adaj.2021.08.011>


Copyright © 2020 American Dental Association. Published by Elsevier Inc. All rights reserved.



Educating for Dental Excellence

<https://world-dental-congress.org/>





THE BEST DENTISTRY LINE IN THE WORLD



cod. 9768



cod. 8007

DEMONSTRATIVE LINE

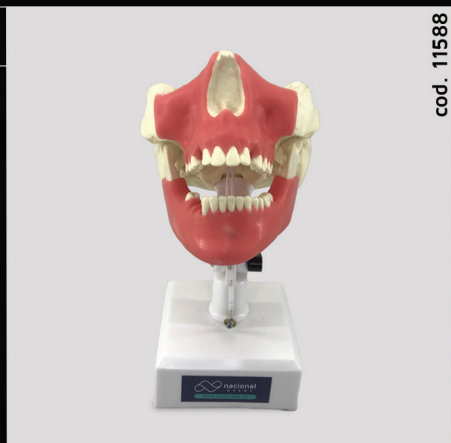MODELS FOR DEMONSTRATING ORAL REHABILITATION TECHNIQUES AND IMPLANTS FOR PATIENTS OR STUDENTS.

THEY ARE EXCELLENT SALES TOOLS THAT ALLOW YOU TO EXPLAIN TREATMENTS IN A CLEAR AND DIDACTIC WAY.

TRAINING LINE

DEVELOPED WITH INTERNAL AND EXTERNAL ANATOMICAL CHARACTERISTICS AND MECHANICAL PROPERTIES VERY CLOSE TO NATURAL BONE. THEY ARE IDEAL FOR HANDS ON AND TRAINING IN IMPLANT SURGICAL PRACTICES. THEY CAN BE DRILLED, CUT AND HAVE SOFT TISSUE SIMULATION THAT ALLOWS INCISION AND SUTURE.

THE ENTIRE TRAINING LINE CAN BE RADIOPAQUE.



cod. 11588



cod. 30PCF-CP3

EFFECTS OF MASTICATORY MOVEMENTS ON THE HEAD, TRUNK AND BODY SWAY DURING THE STANDING POSITION

Kiwamu Sakaguchi^{1a}, Keiko Shima^{1b}, Noshir R. Mehta^{2c}, Tomoaki Maruyama^{3d}, Leopoldo P. Correa^{2e}, Atsuro Yokoyama^{1f}

¹Division of Oral Functional Science, Graduate, Department of Oral Functional Prosthodontics, School of Dental Medicine, Hokkaido University, Sapporo, Japan

²Craniofacial Pain Center, Department of Diagnostic Sciences, Tufts University School of Dental Medicine, Boston, MA, USA

³Computer Science Course, Department of Industrial Engineering, National Institute of Technology (KOSEN), Ibaraki College, Hitachinaka, Japan

^aDDS, PhD, Associate Professor; e-mail: sakaguti@den.hokudai.ac.jp; ORCIDiD: <https://orcid.org/0000-0002-5955-3043>

^bDDS, PhD; e-mail: shimak@den.hokudai.ac.jp


^cDMD, MDS, MS, Professor Emeritus; e-mail: noshir.mehta@tufts.edu; ORCIDiD: <https://orcid.org/0000-0003-0360-9535>

^dPhD, Associate Professor; e-mail: maruyama@ee.ibaraki-ct.ac.jp; ORCIDiD: <https://orcid.org/0000-0002-0553-4787>

^eBDS, MS, Associate Professor; e-mail: leopoldo.correa@tufts.edu

^fDDS, PhD, Professor; e-mail: yokoyama@den.hokudai.ac.jp; ORCIDiD: <https://orcid.org/0000-0003-4763-418>

ABSTRACT

 [https://doi.org/10.25241/stomaedu.2022.9\(3-4\).art.1](https://doi.org/10.25241/stomaedu.2022.9(3-4).art.1)

Introduction Mastication involves complex tongue movements, coordination of lip, and cheek movements and is associated with head movement to facilitate the intraoral transport of food from ingesting to swallowing; it affects many functions of the whole body. However, studies to evaluate the relationship between masticatory movements and the body posture are still lacking to our knowledge. The purpose of this study was to characterize the effects of masticatory movements on the head, trunk, and body sway during the standing position.

Methodology A total of 30 healthy subjects were evaluated. The MatScanTM system was used to analyze changes in body posture (center of foot pressure: COP) and the 3-dimensional motion analysis system was used to analyze changes in the head and trunk postures while subjects remained in the standing position with the rest position, centric occlusion, and masticating chewing gum.

Results The total trajectory length of COP and head and trunk sways during masticating chewing gum were significantly shorter and smaller respectively than it was in the rest position and centric occlusion ($p < 0.016$). COP area during masticating chewing gum was significantly smaller than it was in the 2 mandibular positions ($p < 0.016$).

Conclusion Masticatory movements positively affect the stability of the head, trunk, and body sways and enhance the postural stability during the standing position.

KEYWORDS

Masticatory Movements; Head, Trunk, and Body Sways; Changing Body Posture; Standing Position; Postural Stability

1. INTRODUCTION


One of the purposes in dental prosthetic treatment includes the recovery of the masticatory function. Mastication involves not only simple sequential jaw-opening and jaw-closing movements but also complex tongue movements, coordination of lip, and cheek movements and is associated with head movement to facilitate the intraoral transport of food from ingesting to swallowing [1-3].

It has been reported that masticatory movements affect many functions of the whole body, including the awakening effect [4,5], promotion of cerebral function [6], reaction latency to external disturbances [7], and are closely related to health promotion [8].

There is a report in the literature that the head moves

in rhythmical coordination with the mandibular movement during mastication [9]. The height of the body's center of mass is somewhere between 55% (women) and 57% (men) of the standing height [10], and the small area of the sole of the foot supports the weight of the whole body. Therefore, stability in head posture is indispensable to the control of the body posture during the standing position.

Previous studies have analyzed the relationships between the mandibular position and body posture [11,12]. Further studies have discussed relationships between mastication and the static [13,14] and dynamic [7] balance of body posture, leg muscle activity [15], neck muscle activity [16], head position [17], and upper half of body [18].

 **OPEN ACCESS** This is an Open Access article under the CC BY-NC 4.0 license.

Peer-Reviewed Article

Citation: Sakaguchi K, Shima K, Mehta NR, Maruyama T, Correa LP, Yokoyama A. Effects of masticatory movements on the head, trunk and body sway during the standing position. *Stoma Edu J.* 2022;9(3-4):81-87.

Received: October 06, 2022; **Revised:** October 29, 2022; **Accepted:** November 05, 2022; **Published:** November 15, 2022.

***Corresponding author:** Kiwamu Sakaguchi, Division of Oral Functional Science, Department of Oral Functional Prosthodontics, Graduate School of Dental Medicine, Hokkaido University, Sapporo, Japan.

Tel.: +81-11-706-4270; **Fax:** +81-11-706-4903; **e-mail:** sakaguti@den.hokudai.ac.jp

Copyright: © 2022 the Editorial Council for the Stomatology Edu Journal.

However, studies to evaluate the relationship between masticatory movements and the body posture are still lacking to our knowledge. The purpose of this study was to characterize the effect of masticatory movements on head, trunk, and body sways during the standing position.

2. METHODOLOGY

2.1 Study population and ethics

30 healthy students (15 males and 15 females) with an average age of 28.6 years (range 22-32 years) were recruited among the students and staff members of the Graduate School of Dental Medicine Hokkaido University. The sample size was calculated using the software program G*Power 3.1.9.2 (Heinrich-Heine-Universität Düsseldorf). When the sample size was calculated by setting $\alpha = 0.05$, $\beta = 0.8$, and effect size = 0.8, 26 participants were needed. All subjects met the following inclusion criteria: (1) no history of head and neck or back problems, (2) no history of signs and symptoms of temporomandibular disorders or orofacial pain, (3) no history of orthopedic or otolaryngologic problems affecting body balance, (4) absence of prosthesis (i.e., crowns, bridges, implants or removable prosthetics) and class I dental occlusion, and (5) the pattern during mastication assessed by a linear or concave opening path from centric occlusion toward the working side and a subsequent convex closing path in the vicinity of centric occlusion [19].

The movement of the mandibular incisal point during chewing gum on habitual chewing side was recorded by the optical jaw motion tracking device (FUJITA Medical Instruments Co, Japan) and was analyzed using the overlapping of each cycle and average path [19] (Fig. 1).

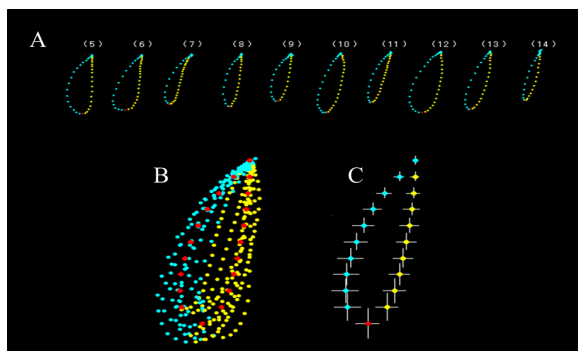


Figure 1. An example of overlapping of cycle and average path during chewing on the right side. Using the centric occlusion of each cycle as the standard, coordinates for each cycle were determined by vertically dividing the opening and closing paths into 10 equally spaced sections in the frontal view. From these coordinates, the average path and SD (standard deviation) were calculated. The method used to calculate the average path is as follows: (A) 5-14 cycles on the habitual side chewing were recorded, and the coordinates for each cycle were determined by vertical division into 10 equally spaced sections. (B) Overlapping of each cycle and average path. (C) Average path and SDs of each level.

This study was approved by the ethical committee of the Graduate School of Dental Medicine Hokkaido University (2019-No.2). The study methodology was explained, and written consent was obtained from all participants prior to their inclusion in the study.

2.2 Analysis of simultaneous measurements of head, trunk, and body sways (Fig. 2)

The MatScan™ system (Tekscan Inc., Boston, MA, Nitta Corp., Osaka, Japan) was used to analyze body sway [11,12,20]. This instrument provided a dynamic evaluation of body posture. This system could measure weight distribution and changes in the position of the center of foot pressure (COP) on a footplate during a standard measuring period. The COP is the center of vertical force acting on the support surface. It indicates gravity shifts in the anteroposterior and lateral directions.

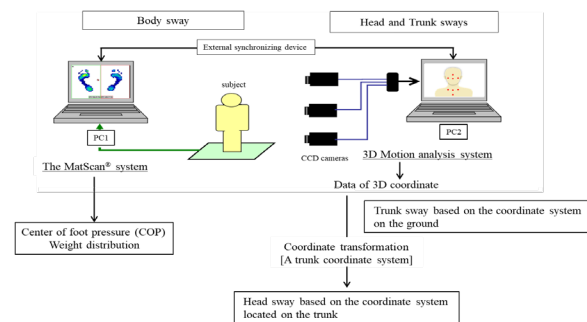


Figure 2. Analysis of simultaneous measurements of the head, trunk and body sways. Data sampling was performed simultaneously at a sampling rate of 60 Hz using a self-made external synchronization device. For the head and trunk sway measurements, a three-dimensional motion analysis system (Library Co., Ltd., Tokyo, Japan) was used to analyze the motion of the target points set on the head and trunk respectively. In the head sway analysis, the coordinates were transformed to a coordinate system, a trunk coordinate system, based on the trunk to eliminate the trunk sway. The center of foot pressure (COP) and weight distribution were measured using a footplate, the MatScan™ system (Tekscan Inc., Boston, MA, Nitta Corp., Osaka, Japan). CCD: Charge coupled device.

The three-dimensional motion analysis system (Library Co., Ltd, Tokyo, Japan) was used to analyze head and trunk sways. This instrument enabled the measurement of the three-dimensional movements of target points on the surface of the facial skin and body surface simultaneously. The movements of the target points were recorded by three charge coupled device (CCD) cameras, and the three-dimensional coordinates were calculated by using an analyzing software (Library Co., Ltd, Tokyo, Japan). The target points on the face and trunk skin were marked by attaching 4 points respectively (Fig. 3).

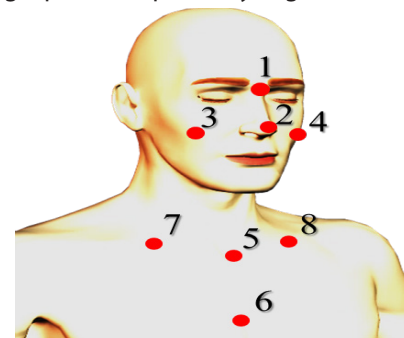


Figure 3. Target points set on the head and trunk. Four target points were set on the head (No. 1-4) and trunk (No. 5-8) respectively for the motion analysis. No. 1: nasion, No. 2: top of the nose, No. 3 and 4: right and left zygomatic bones, No. 5: jugular notch, No. 6: xiphoid process, No. 7 and 8: right and left clavicle middle point. Round reflecting markers (10 mm in diameter) were used as target points to be recognized by using their luminance values, and double-sided tape was used for setting these markers on the head and trunk luminance values.

The center of the 4 target points was calculated in each sampling frame. Then the mean coordinate of all the centers of the 4 target points on the face was defined as the virtual central coordinate of the head (MCB-h). In the same way, the mean coordinate of all the centers of the 4 target points on the trunk was defined as the virtual central coordinate of the trunk (MCB-t). The head sway was analyzed based on the coordinate system located on the trunk (A trunk coordinate system). The trunk sway was analyzed based on the coordinate system on the ground.

For all tests, the subjects were asked to remove their shoes and socks, to stand with their feet apart to the width of their shoulders in a natural stance on the force platform of the MatScan™ system. To assist in obtaining the natural standing posture, the subjects were asked to look directly into a reflected image of their eyes, two meters away with arms hanging free at their sides and to remain in this position during the measurements. Simultaneous measurement of the head, trunk, and body sways was conducted under the following three conditions: (1) The subjects maintained the rest position (teeth slightly apart and masticatory muscles in a relaxed non-contractile condition). (2) The subjects maintained the centric occlusion without clenching. (3) The subjects chew softened chewing gum on their habitual chewing side and were requested not to swallow it for the time tested. These three conditions were randomly conducted in each subject, based on the table of random numbers. Testing under each condition was recorded for 20 seconds. The recording was started after the subject stood on the MatScan™ sensor and the investigator confirmed that their head and body positions were stable. Each trial was recorded three times with a one-minute rest period.

2.3 Parameters

The total trajectory length of the COP and COP areas (Rectangular area, Outer peripheral area, Root mean square area) were used to evaluate the stability of the body posture [11,12]. Each trial of the MatScan™ system was recorded in 1200 frames for 20 seconds. The 2-dimensional coordinates of the COP were acquired for every frame. First, the effective distance of the COP between one frame and the next frame was calculated based on the pitch of the sensor sheet in each trial. The total trajectory length of the COP for each trial was then calculated by summing up all the effective distances of the COP between 1200 consecutive frames. The COP areas were the rectangular area, the outer peripheral area, and the root mean square area of the total trajectory of 1200 COPs respectively.

The lateral and anteroposterior weight distribution were used to evaluate the balance of body posture [11,12]. A four-quadrant weight distribution value was measured in percentages (%) for every frame in each trial (Fig. 4). First, the lateral weight distribution and the anteroposterior weight distribution values for each frame were calculated. Next, the mean value of the sum of all lateral weight distribution

values in each trial was calculated (LWD). The same calculation was carried out for the anteroposterior weight distribution value (AWD). The calculation for the LWD and AWD was as follow: $LWD (\%) = 50 - (\text{the right-anterior value} + \text{the right-posterior value})$, and $AWD (\%) = 50 - (\text{the right-posterior value} + \text{the left-posterior value})$.

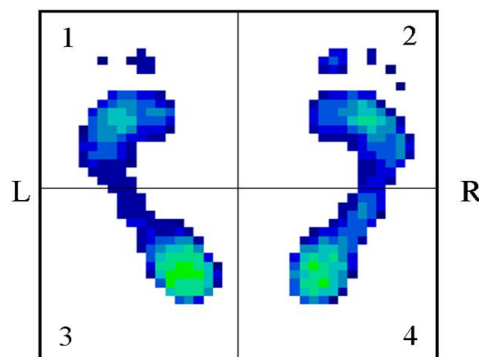


Figure 4. A four-quadrant weight distribution. Pressure at the soles of both feet was measured in equalized four-quadrant sections: (1) left anterior, (2) right anterior, (3) left posterior, and (4) right posterior. L: left side, R: right side.

The head and trunk sway values were used to evaluate the stability of the head and trunk position respectively. Each trial of the three-dimensional motion analysis system was recorded in 1200 frames for 20 seconds. The 3-dimensional coordinate of the center of the 4 target points of the head was acquired for every frame. The head sway value was defined as the mean distance between MCB-h and each center of the 4 target points. The trunk sway value was obtained in the same manner as the head sway value.

Each trial was repeated three times and the average value of the three trials was used as the representative value for each subject.

2.4 Statistical analysis

The total trajectory length of the COP, the COP areas (Rectangle area, Outer peripheral area, Root mean square area), the lateral and anteroposterior weight distribution and the head and trunk sway values were compared to evaluate whether the masticatory movements affected the head, trunk, and body sways. All comparisons were performed using Friedman's two-way analysis of variance ($p < 0.05$) and the Wilcoxon t-test with Bonferroni correction ($0.05/3 = 0.016$) were used. SPSS version 21 (SPSS Japan Inc., Tokyo, Japan) was used for statistical analysis.

3. RESULTS

The results of the comparisons (median values) in total trajectory length of COP among the rest position, centric occlusion, and masticating chewing gum are shown in Fig. 5. The total trajectory length of COP in the centric occlusion was significantly shorter than it was in the rest position. The total trajectory length of COP during masticating chewing gum was significantly shorter than it was in the rest position and in centric occlusion.

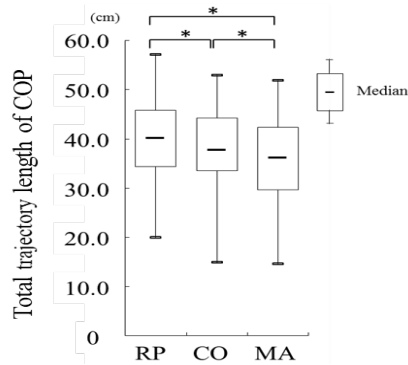


Figure 5. Comparison of total trajectory length of COP among rest position (RP), centric occlusion (CO), and masticating chewing gum (MA). Differences among RP, CO, and MA were tested with the Friedman's two-way analysis of variance ($P < 0.05$), and multiple comparisons was assessed by the Bonferroni adjustment ($0.05/3 = 0.016$) after Wilcoxon t-test. *: $P < 0.016$, and $n = 30$. Medians (IQR) of RP, CO, and MA were as follows: RP 40.2(34.4 - 45.9), CO 37.7(33.5 - 44.3), MA 36.2(29.6 - 42.4).

The median COP areas (Rectangle area, Outer peripheral area, Root mean square area) are shown in Fig. 6. The median COP areas in the centric occlusion were significantly smaller than it was in the rest position. The median COP areas during masticating chewing gum were significantly smaller than they were in the rest position.

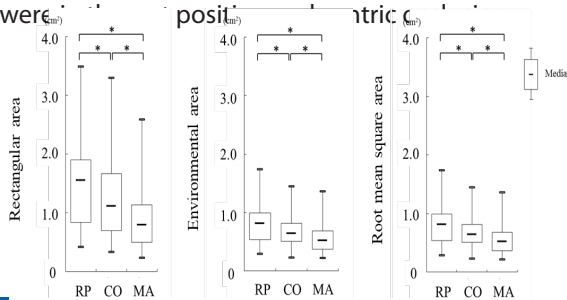


Figure 6. Comparison of COP areas (rectangle area, outer peripheral area, and root mean square area) among RP, CO, and MA. *: $P < 0.016$, and $n = 30$. Medians (IQR) of RP, CO, and MA for rectangle area were as follows: RP 1.6(0.8-1.9), CO 1.1(0.7-1.7), MA 0.8(0.5-1.1). Medians (IQR) of RP, CO, and MA for outer peripheral area were as follows: RP 0.8(0.5-1.0), CO 0.6(0.5-0.8), MA 0.5(0.4-0.7). Medians (IQR) of RP, CO, and MA for root mean square area were as follows: RP 0.8(0.5 - 1.0), CO 0.6(0.5 - 0.8), MA 0.5(0.4 - 0.7).

The results of the comparisons (median values) in the lateral and anteroposterior weight distributions among the rest position, centric occlusion, and masticating chewing gum are shown in Fig. 7. There were no significant differences in the distribution of foot pressure among the rest position, centric occlusion, and masticating chewing gum.

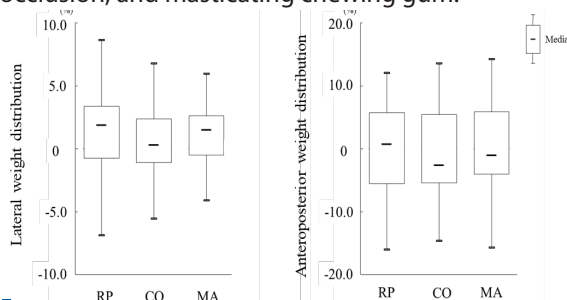


Figure 7. Comparison of lateral and anteroposterior weight distributions among RP, CO, and MA. All comparisons were not significant ($P > 0.016$), and $n = 30$. Medians (IQR) of RP, CO, and MA for lateral weight distribution were as follows: RP 1.9(-0.8-3.4), CO 0.3(-1.1-2.4), MA 1.5(-0.5-2.6). Medians (IQR) of RP, CO, and MA for anteroposterior weight distribution were as follows: RP 0.7(-5.5 - 5.7), CO -2.6(-5.4 - 5.4), MA -1.1(-4.0 - 5.9).

The results of the comparisons (median values) in the head and trunk sway values among the rest position, centric occlusion, and masticating chewing gum are shown in Fig. 8. The head and trunk sway values in the centric occlusion were significantly smaller than they were in the rest position. The head and trunk sway values during masticating chewing gum were significantly smaller than they were in the rest position and centric occlusion.

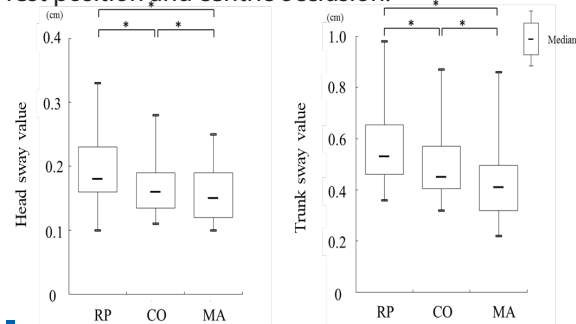


Figure 8. Comparison of head and trunk sway values among RP, CO, and MA. *: $P < 0.016$, and $n = 30$. Medians (IQR) of RP, CO, and MA for head sway value were as follows: RP 0.18(0.16 - 0.23), CO 0.16(0.14 - 0.19), MA 0.15(0.12 - 0.19). Medians (IQR) of RP, CO, and MA for trunk sway value were as follows: RP 0.53(0.46 - 0.66), CO 0.45(0.41 - 0.57), MA 0.41(0.32 - 0.50).

4. DISCUSSION

The results for the total trajectory length of COP (Fig. 5), COP areas (Rectangle area, Outer peripheral area, and Root mean square area) (Fig. 6), head and trunk sway values (Fig. 8) suggested that the body posture was significantly more stable when the subjects bit down in centric occlusion than when they maintained their mandibles in the rest position. Stability in the head position is indispensable to the control of the body posture. The anterior and posterior cervical muscles are concerned with the stability and movement of the head [21-24]. The loss of posterior occlusal support deprives the stomatognathic system of valuable proprioceptive information, and likely alters muscle contraction patterns. These changes are reported to effect the cervical muscles through the trigeminal nerve [16]. The cervical nerves C1 to C4 are primarily involved in controlling head posture [25] and the proprioceptive inputs from the muscles and articulations of the neck are important in the maintenance of postural balance [26]. Stimulation of the vestibular system by changing the head position has a descending influence on the triceps surae muscle and the soleus muscle, both antigravity muscles [27]. Based on these previous reports, the stability of the head is maintained through the action of the cervical area. The present result found that the body posture was significantly more stable in the centric occlusion than in the rest position, and suggests that bilateral occlusal contacts in the centric occlusion caused a change bilaterally in the peripheral inputs from each organ in the stomatognathic system and resulted in improving both the stability of the neck, the head, and the trunk positions. Consequently, body posture was more stable when the subjects bit down in the centric occlusion compared to when they maintained in a muscular rest position.

The results for the total trajectory length of COP (Fig. 5), COP areas (Rectangle area, Outer peripheral area, and Root mean square area) (Fig. 6), head and trunk sway values (Fig. 8) suggested that the body posture was significantly more stable when the subjects masticated chewing gum than when they bit down in centric occlusion or they maintained their mandibles in a muscular rest position.

Yagi et al. [26] reported that the leg muscles, which directly regulate the movement of the ankle joint, and the dorsal neck muscles, which change the static equilibrium through the central nervous system, are important for maintaining the standing posture. Takahashi et al. [15] indicated that the H reflexes in both the pretibial and soleus muscles undergo a nonreciprocal facilitation during mastication. Takada et al. [28] found the increase in amplitude of the pretibial and soleus H reflex showed a positive correlation with the strength of teeth clenching. Lundgren and Laurell [29] confirmed on average 37% of the total maximal bite force in habitual occlusion was utilized during chewing. Moreover, Watanabe et al. [30] suggested that the pattern of masticatory movement path with a linear or concave opening path and a convex closing path (Pattern I) had the stability of the path and rhythm and a superior masticatory function compared to the pattern of the masticatory movement path with a similar open path to that in Pattern I and a concave closing path.

The present results found that the body posture was significantly more stable when the subjects masticated chewing gum than when they bit down in centric occlusion or maintained their mandible in the rest position (Figs. 5, 6 and 8). Based on the previous reports [15,26,28-30], one can infer that when the subjects masticated chewing gum, the occlusal force might have been larger compared to it in centric occlusion, and the pattern of the masticatory movement path had the stability of the path and rhythm and a superior masticatory function. Moreover, the present results showed the possibility that the peripheral inputs from each organ in the stomatognathic system during mastication may have strongly affected the muscles, pretibial and soleus muscle, and the upper central nervous system, which regulate the craniocervical muscles, as the positive feedback control to maintain and stabilize the standing posture. Namely, a positive impact to the posture control system during mastication may have extended to both the upper and lower extremities. Consequently, the mastication movement may have affected the postural control by enhancing the postural stability standing position.

Stable human standing is usually considered to depend on an integrated reflex response to vestibular, visual, and somatosensory input [31]. When the center of gravity changes its position in space, the neuromuscular system must compensate so that the center of gravity remains in a balanced position [21]. The present results found that there were no significant differences in the distribution of the foot pressure among the rest position, centric occlusion, and masticating chewing gum anteroposteriorly and laterally (Fig. 7). These results suggest that changes in mandibular position and masticating chewing gum did not affect the postural balance anteroposteriorly and laterally.

4.1 Limitations

This study has some limitations. The simultaneous measurements of head, trunk, and body sways were carried out to evaluate a relationship between the stomatognathic function and body posture in the present study. However, analyses were not done on the motion analysis of the lower legs and muscle activities in the head, neck, trunk, and lower legs. The future direction of study should be to include the motion analysis of the lower legs and the analysis of electrical activities of craniocervical and whole body muscles to elucidate the relationship between mastication and body posture in detail. Moreover, it also needs further analysis on the subjects with the other patterns of masticatory movement path other than Pattern I (the pattern of masticatory movement path with a linear or concave opening path and a convex closing path) [30]. Kushiro et al. [13] investigated the effect of masticating chewing gum on the postural stability during upright standing, using only the force plate for postural assessment, and they suggested that mastication of chewing gum affects the postural control by enhancing the postural stability during upright standing. Goto et al. [14] also conducted a similar study and reported that the chewing gum indirectly affected postural control by influencing the vestibular function to stabilize posture during upright standing. Our results in the present study, which were obtained by adding the motion analysis to the force plate analysis, corroborate these previous studies, and suggest that the jaw sensory motor system can modulate postural control mechanisms. Gum chewing activity can enhance postural stability during upright standing in healthy young adults. Detailed investigations on the mechanism underlying these effects should be performed in future studies. Our findings could be taken into consideration in treatment and rehabilitation planning for some patients with postural instability due to balance disorders.

5. CONCLUSION

Masticatory movements affect the head, trunk, and body sways and enhance the postural stability during standing position.

CONFLICT OF INTEREST

No potential conflict of interest was reported by the authors.

FUNDING

This study was supported by JSPS KAKENHI Grant Numbers JP15K11188 and JP19K10219.

AUTHOR CONTRIBUTIONS

KS: data gathering and analysis, literature collection and writing some parts of manuscript. **KS:** concept and design, protocol, data gathering and analysis, their interpretation and drafting the manuscript, manuscript revision and submission. **NRM:** concept and design, data interpretation, critical revision of the manuscript for important intellectual content. **TM:** technical support of the measurement system. **LPC:** concept and design, critically revised the manuscript. **AY:** administrative, technical, and material support; study supervision. All authors read and approved the final manuscript.

REFERENCES

1. Hori K, Ono T, Nokubi T. Coordination of tongue pressure and jaw movement in mastication. *J Dent Res.* 2006;85(2):187-191. doi: 10.1177/154405910608500214. PMID: 16434740.
[Full text links](#) [CrossRef](#) [PubMed](#) [Google Scholar](#) [Scopus](#) [WoS](#)
2. Sakaguchi K, Maeda N, Yokoyama A. Examination of lower facial skin movements during left- and right-side chewing. *J Prosthodont Res.* 2011;55(1):32-39. doi: 10.1016/j.jpor.2010.08.002. PMID: 20947466.
[Full text links](#) [CrossRef](#) [PubMed](#) [Google Scholar](#) [Scopus](#) [WoS](#)
3. Taniguchi H, Matsuo K, Okazaki H, et al. Fluoroscopic evaluation of tongue and jaw movements during mastication in healthy humans. *Dysphagia.* 2013;28(3):419-427. doi: 10.1007/s00455-013-9453-1. PMID: 23446812.
[Full text links](#) [CrossRef](#) [PubMed](#) [Google Scholar](#) [Scopus](#) [WoS](#)
4. Momose T, Nishikawa J, Watanabe T, et al. Effect of mastication on regional cerebral blood flow in human examined by positron-emission tomography with 15O-labelled water and magnetic resonance imaging. *Arch oral Biol.* 1997;42(1):57-61. doi: 10.1016/S0003-9969(96)00081-7. PMID: 9134116.
[Full text links](#) [CrossRef](#) [PubMed](#) [Google Scholar](#) [Scopus](#)
5. Ono Y, Yamamoto T, Kubo K, Onozuka M. Occlusion and brain function: mastication as a prevention of cognitive dysfunction. *J Oral Rehabil.* 2010;37(8):624-640. doi: 10.1111/j.1365-2842.2010.02079.x. PMID: 20236235.
[Full text links](#) [CrossRef](#) [PubMed](#) [Google Scholar](#) [Scopus](#) [WoS](#)
6. Hirano Y, Obata T, Kashikura K, et al. Effects of chewing in working memory processing. *Neurosci Lett.* 2008;436(2):189-192. doi: 10.1016/j.neulet.2008.03.033. PMID: 18403120.
[Full text links](#) [CrossRef](#) [PubMed](#) [Google Scholar](#) [Scopus](#) [WoS](#)
7. Kaji K, Katoh M, Isozaki K, et al. The effect of mastication on reaction latency to unanticipated external disturbances in the standing position. *J Med Dent Sci.* 2012;59(4):83-88. PMID: 23897116.
[PubMed](#) [Google Scholar](#) [Scopus](#)
8. Miura H, Miura K, Mizugai H, et al. Chewing ability and quality of life among the elderly residing in a rural community in Japan. *J Oral Rehabil.* 2000;27(8):731-734. doi: 10.1046/j.1365-2842.2000.00590.x. PMID: 10931271.
[Full text links](#) [CrossRef](#) [PubMed](#) [Google Scholar](#) [Scopus](#) [WoS](#)
9. Häggman-Henrikson B, Eriksson PO. Head movements during chewing: relation to size and texture of bolus. *J Dent Res.* 2004;83(11):864-868. doi: 10.1177/154405910408301108. PMID: 15505237.
[Full text links](#) [CrossRef](#) [PubMed](#) [Google Scholar](#) [Scopus](#) [WoS](#)
10. Virmavirta M, Isolehto J. Determining the location of the body's center of mass for different groups of physically active people. *J Biomech.* 2014;47(8):1909-1913. doi: 10.1016/j.jbiomech.2014.04.001. PMID: 24742487.
[Google Scholar](#) [Scopus](#) [WoS](#)
11. Sakaguchi K, Mehta NR, Abdallah EF, et al. Examination of the relationship between mandibular position and body posture. *Cranio.* 2007;25(4):237-249. doi: 10.1179/crn.2007.037. PMID: 17983123.
[Full text links](#) [CrossRef](#) [PubMed](#) [Google Scholar](#) [Scopus](#) [WoS](#)
12. Maeda N, Sakaguchi K, Mehta NR, et al. Effects of experimental leg length discrepancies on body posture and dental occlusion. *Cranio.* 2011;29(3):194-203. doi: 10.1179/crn.2011.028. PMID: 22586828.
[Full text links](#) [CrossRef](#) [PubMed](#) [Google Scholar](#) [Scopus](#) [WoS](#)
13. Kushiro K, Goto F. Effect of masticating chewing gum on postural stability during upright standing. *Neurosci Lett.* 2011;487(2):196-198. doi: 10.1016/j.neulet.2010.10.021. PMID: 20959136.
[Full text links](#) [CrossRef](#) [PubMed](#) [Google Scholar](#) [Scopus](#) [WoS](#)
14. Goto F, Kushiro K, Tsutsumi T. Effect of chewing gum on static posturography in patients with balance disorders. *Acta Otolaryngol.* 2011;131(11):1187-1192. doi: 10.3109/00016489.2011.607846. PMID: 21892900.
[Full text links](#) [CrossRef](#) [PubMed](#) [Google Scholar](#) [Scopus](#) [WoS](#)
15. Takahashi T, Ueno T, Taniguchi H, et al. Modulation of H reflex of pretibial and soleus muscles during mastication in humans. *Muscle Nerve.* 2001; 24(9):1142-1148. doi: 10.1002/mus.1125. PMID: 11494266.
[Full text links](#) [CrossRef](#) [PubMed](#) [Google Scholar](#) [Scopus](#) [WoS](#)
16. Häggman-Henrikson B, Nordh E, Eriksson PO. Increased sternocleidomastoid, but not trapezius, muscle activity in response to increased chewing load. *Eur J Oral Sci.* 2013;121(5):443-449. doi: 10.1111/eos.12066. PMID: 24028592.
[CrossRef](#) [Google Scholar](#)
17. Shinya A, Sato T, Hisanaga R, et al. Time course analysis of influence of food hardness on head posture and pitching of head during masticatory movement. *Bull Tokyo Dent Coll.* 2013;54(2):73-80. doi: 10.2209/tdcpub.54.73. PMID: 903577.
[Full text links](#) [CrossRef](#) [PubMed](#) [Google Scholar](#) [Scopus](#)
18. Inada E, Saitoh I, Nakakura-Ohshima K, et al. Association between mouth opening and upper body movement with intake of different-size food pieces during eating. *Arch Oral Biol.* 2012;57(3):307-313. doi: 10.1016/j.archoralbio.2011.08.023. PMID: 21975117.
[Full text links](#) [CrossRef](#) [PubMed](#) [Google Scholar](#) [Scopus](#) [WoS](#)
19. Kobayashi Y, Shiga H, Arakawa I, et al. Masticatory path pattern during mastication of chewing gum with regard to gender difference. *J Prosthodont Res.* 2009;53(1):11-14. doi: 10.1016/j.jpor.2008.08.002. PMID: 19318065.
[Full text links](#) [CrossRef](#) [PubMed](#) [Google Scholar](#) [Scopus](#) [WoS](#)
20. Zammit GV, Menz HB, Munteanu SE. Reliability of the TekScan MatScan (R) system for the measurement of plantar forces and pressures during barefoot level walking in healthy adults. *J Foot Ankle Res.* 2010;3:11-19. doi: 10.1186/1757-1146-3-11. PMID: 20565812.
[Full text links](#) [CrossRef](#) [PubMed](#) [Google Scholar](#) [WoS](#)
21. Bracco P, Deregibus A, Piscetta R, Ferrario G. Observations on the correlation between posture and jaw position: a pilot study. *Cranio.* 1998;16(4):252-258. doi: 10.1080/08869634.1998.11746065. PMID: 10029753.
[Full text links](#) [CrossRef](#) [PubMed](#) [Google Scholar](#) [Scopus](#) [WoS](#)
22. Nicolakis P, Nicolakis M, Piehslinger E, et al. Relationship between craniomandibular disorders and poor posture. *Cranio.* 2000;18(2):106-112. doi: 10.1080/08869634.2000.11746121. PMID: 11202820.
[Full text links](#) [CrossRef](#) [PubMed](#) [Google Scholar](#) [Scopus](#) [WoS](#)
23. Milani RS, De Perière DD, Lapeyre L, Pourreyron L. Relationship between dental occlusion and posture. *Cranio.* 2000;18(2):127-134. doi: 10.1080/08869634.2000.11746124. PMID: 11202823.
[Full text links](#) [CrossRef](#) [PubMed](#) [Google Scholar](#) [Scopus](#) [WoS](#)
24. Bracco P, Deregibus A, Piscetta R. Effects of different jaw relations on postural stability in human subjects. *Neurosci Lett.* 2004;356(3):228-230. doi: 10.1016/j.neulet.2003.11.055. PMID: 15036636.
[Full text links](#) [CrossRef](#) [PubMed](#) [Google Scholar](#) [Scopus](#)
25. Bogduk N. The clinical anatomy of the cervical dorsal rami. *Spine.* 1982;7(4):319-330. doi: 10.1097/00007632-198207000-00001. PMID: 71350
[CrossRef](#) [PubMed](#) [Google Scholar](#)
26. Yagi Y, Yajima H, Sakuma A, Aihara Y. Influence of vibration to the neck, trunk and lower extremity muscles on equilibrium in normal subjects and patients with unilateral labyrinthine dysfunction. *Acta Otolaryngol.* 2000;120(2):182-186. doi: 10.1080/000164800750000874. PMID: 11603768.
[Full text links](#) [CrossRef](#) [PubMed](#) [Google Scholar](#) [Scopus](#)
27. Kawanokuchi J, Fu Q, Cui J, et al. Influence of vestibulo-sympathetic reflex on muscle sympathetic outflow during head-down tilt. *Environ Med.* 2001;45(2):66-68. PMID: 12353535.
[PubMed](#) [Google Scholar](#)
28. Takada Y, Miyahara T, Tanaka T, et al. Modulation of H reflex of pretibial muscles and reciprocal Ia inhibition of soleus muscle during voluntary teeth clenching in humans. *J Neurophysiol.* 2000;83(4):2063-2070. doi: 10.1152/jn.2000.83.4.2063. PMID: 10758116.
[Full text links](#) [CrossRef](#) [PubMed](#) [Google Scholar](#) [Scopus](#) [WoS](#)
29. Lundgren D, Laurell L. Occlusal force pattern during chewing and biting in dentitions restored with fixed bridges of cross-arch extension. I. Bilateral end abutments. *J Oral Rehabil.* 1986;13(1):57-71. doi: 10.1111/j.1365-2842.1986.tb01556.x. PMID: 3511198.
[Full text links](#) [CrossRef](#) [PubMed](#) [Google Scholar](#) [Scopus](#)
30. Watanabe A, Shiga H, Kobayashi Y. Occlusal contacting condition and masticatory function of 2 types of pattern that differ in the closing path of the mandibular incisal point during chewing. *J Prosthodont Res.* 2011;55(4):243-247. doi: 10.1016/j.jpor.2011.03.004. PMID: 21531190.
[Full text links](#) [CrossRef](#) [PubMed](#) [Google Scholar](#) [Scopus](#) [WoS](#)
31. Fitzpatrick R, Rogers DK, McCloskey DI. Stable human standing with lower-limb muscle afferents providing the only sensory input. *J Physiol.* 1994;480(2):395-403. doi: 10.1113/jphysiol.1994.sp020369. PMID: 7869254.
[Full text links](#) [CrossRef](#) [PubMed](#) [Google Scholar](#) [Scopus](#) [WoS](#)

Kiwamu SAKAGUCHI

DMD, MDS, MS, Associate Professor
Division of Oral Functional, Department of Oral Functional Prosthodontics
Graduate School of Dental Medicine
Hokkaido University
Kita-ku, Sapporo, Japan

**CV**

Kiwamu Sakaguchi is an Associate Professor at the Department of Oral Functional Prosthodontics, Division of Oral Functional Science, Graduate School of Dental Medicine, Hokkaido University, Japan. He received his DDS at the Hokkaido University in 1995 and his PhD from the same university in 1999. He joined the Craniofacial Pain Center at Tufts University where he engaged in research from 2003 till 2004.

Questions**1. What other movements are involved in mastication besides the simple sequential jaw-opening and jaw-closing movements?**

- a. Complex tongue movements;
- b. Coordination of lip, and cheek movements;
- c. Head movement to facilitate the intraoral transport of food from ingesting to swallowing;
- d. All.

2. Which of the following is not an inclusionary criteria for this study?

- a. No history of head and neck or back problems;
- b. No history of signs and symptoms of temporomandibular disorders or orofacial pain;
- c. No history of orthopedic or otolaryngologic problems affecting body balance;
- d. Malocclusion.

3. Which statistical tests were used to assess comparisons of the data in this study?

- a. Friedman's two-way analysis of variance;
- b. Wilcoxon t-test with Bonferroni correction;
- c. Both;
- d. None.

4. Which of the following is a conclusion of this study?

- a. Masticatory movements affect head, trunk, and body sways and enhance the postural stability during standing position;
- b. Masticatory movements affect head, trunk, and body sways and deteriorate the postural stability during standing position;
- c. Jaw clenching affect head, trunk, and body sways and enhance the postural stability during standing position;
- d. Bruxism affect head, trunk, and body sways and enhance the postural stability during standing position.

LOW-LEVEL LASER PERIODONTAL THERAPY IN DIABETIC PATIENTS: A RANDOMIZED CONTROLLED CLINICAL TRIAL - PILOT STUDY

Fares Al Hajeb^{1a}, Hala Zakaria^{2b}, Jovita D'Souza^{3c}, Wael Hamsho^{4d}, Omar Al Jadaan^{5e}, Jumma Al Khabuli^{6f}

¹Department of Dentistry, Healthpoint Hospital, Mubadala Health, Abu Dhabi, UAE

²Department of Oral Radiology and Diagnosis, Faculty of Dentistry, British University of Egypt, Cairo, Egypt

³Department of Periodontics and Oral Implantology, College of Dentistry, Gulf Medical University, Ajman, UAE

⁴RAK College of Dental Sciences, RAK Medical and Health Sciences University, Ras Al Khaimah, UAE

⁵Computer Science Engineering, RAK Medical and Health Sciences University, Ras Al Khaimah, UAE

⁶Department of Oral Pathology, College of Dental Medicine, QU Health, Qatar University, Doha, Qatar

^aBDS, Intern; e-mail: faresalhajeb@hotmail.com; ORCIDiD: <https://orcid.org/0000-0002-9003-5877>


^bBDS, MSc, PhD, Professor; e-mail: hala.zakaria@bue.edu.eg; ORCIDiD: <https://orcid.org/0000-0003-1926-7453>

^cBDS, MDS, Specialist Periodontist, Lecturer; e-mail: dr.jovita@gmu.ac.ae; ORCIDiD: <https://orcid.org/0000-0003-4520-4982>

^dBDS, Intern; e-mail: wael.hamsho@hotmail.com; ORCIDiD: <https://orcid.org/0000-0001-8809-0984>

^ePhD, Associate Professor; e-mail: ojadaan@rakmhsu.ac.ae; ORCIDiD: <https://orcid.org/0000-0003-1504-6442>

^fBDS, MDentSci, FDS RCPDS (Glasg), FICD, PhD, Professor; e-mail: jkhhabuli@qu.edu.qa; ORCIDiD: <https://orcid.org/0000-0001-8099-5076>

 [https://doi.org/10.25241/stomaedu.2022.9\(3-4\).art.2](https://doi.org/10.25241/stomaedu.2022.9(3-4).art.2)

Objectives We aimed to evaluate the effects of low-level laser therapy as an adjunct to non-surgical periodontal therapy in patients with periodontitis and compare the effect on periodontal healing in diabetes mellitus and non-diabetes mellitus patients.

Methodology Ten patients with periodontitis stage II grade B were divided into two groups; Group 1 included 5 non-diabetes mellitus patients with periodontitis, and Group 2 included 5 type 2 diabetes mellitus patients with periodontitis. A 13 mW low-level laser was used in a continuous wave and non-contact mode as an adjunct to scaling and root planning (SRP) in a split-mouth study design "OPTODAN" (Scientific Development and Production Center, Saratov, Russia). The clinical parameters; plaque and gingival index, probing depth, and relative clinical attachment level of the test and control sides of both groups were analyzed at baseline and 1-month post-therapy. Visual analogue scale was used to determine patient discomfort intraoperatively and after 1 week.

Results Statistically, significant improvement was evident in the gingival index, probing depth, and relative clinical attachment level when comparing test and control sides in all patients 1-month post-therapy. There was improvement in gingival index amongst type 2 diabetes mellitus patients in the test group. However, non-diabetes mellitus patients demonstrated superior results especially in probing depth and relative clinical attachment level.

Conclusion The use of low-level laser therapy as an adjunct in periodontal therapy showed overall improvement in gingival inflammation, probing depth, and clinical attachment level. In comparison to non-diabetes mellitus patients, type 2 diabetes mellitus patients demonstrated significant improvement in gingival inflammation with low-level laser therapy.

KEYWORDS

Periodontitis; Diabetes Mellitus; Lasers; Periodontal Pockets; Photobiomodulation

1. INTRODUCTION

The applications of Photobiomodulation (PBM) or Low-Level Laser Therapy (LLLT) are gaining popularity in the field of dentistry. These lasers have wavelengths that range between 600 and 1,100 nm and interact with tissues via non-thermal photochemical and biological mechanisms. The low-level laser (LLL) light is absorbed in the

mitochondria by chromophores including the protein cytochrome-c oxidase which then increases the internal activity and three events occur as a result: An increase in adenosine triphosphate (ATP), the main energy source for the majority of cellular functions which accelerates the healing process; modulation of reactive oxygen species (ROS) which activates transcription factors positively impacting cellular repair and healing; and temporary release

 **OPEN ACCESS** This is an Open Access article under the CC BY-NC 4.0 license.

Peer-Reviewed Article

Citation: Al Hajeb F, Zakaria H, D'Souza J, Hamsho W, Al Jadaan O, Al Khabuli J. Low-Level Laser Periodontal Therapy in Diabetic Patients: A Randomized Controlled Clinical Trial - Pilot Study. *Stoma Edu J.* 2022;9(3-4):88-94.

Received: July 03, 2022; **Revised:** July 23, 2022; **Accepted:** August 23, 2022; **Published:** September 04, 2022.

***Corresponding author:** Prof. Dr. Jumma Al Khabuli, Department of Oral Pathology, College of Dental Medicine, QU Health, Qatar University, Doha, Qatar. e-mail: jkhhabuli@qu.edu.qa.

Copyright: © 2022 the Editorial Council for the Stomatology Edu Journal.

of nitrous oxide (NO), a potent vasodilator, which improves circulation as well as lymphatic drainage. Therefore, clinically these lasers are known to reduce pain, inflammation and promote wound healing. Due to these properties, researchers are constantly striving to find different therapeutic applications of this non-invasive treatment modality [1].

Periodontitis is a multifactorial chronic inflammatory disease that causes progressive destruction of tooth-supporting tissues (gingiva, periodontal ligament, and surrounding bone), eventually resulting in loss of tooth support. The main etiological factor is microbial plaque accumulation at the gingival margin. When allowed to become chronic, drastic consequences in the periodontium occur causing inflammatory changes in the gingiva, which initially appear as redness and bleeding on probing (BOP). With persistence of inflammation and progression of tissue damage; clinical attachment loss (CAL), bone loss and periodontal pocket formation are evident. Several anaerobic gram-negative species are considered the culprits of periodontal disease, mainly; *Porphyromonas gingivalis*, *Aggregatibacter actinomycetemcomitans* and *Fusobacterium nucleatum* [2,3]. The basic principle of periodontal therapy is to restore function and avoid further progression of the periodontal disease by removing or altering the causative factors [4]. Conventional treatment for periodontitis consists of non-surgical methods that involve debridement of the inflamed tissues to control the periodontal infection and allow healing of the periodontium [5,6]. Disruption of biofilm by the mechanical removal of subgingival plaque reduces the bacterial load and facilitates resolution of inflammation as well as decrease the probing depth (PD). Considering that LLL is effective in reducing gingival inflammation, swelling, as well as inducing wound healing and providing pain relief, a lot of research is directed towards understanding if the adjunctive use of these lasers could promote accelerated healing and periodontal tissue regeneration. In a study, Obradović et al. achieved better therapeutic results when LLLT was combined with scaling and root planing (SRP) compared to SRP alone [7].

Various systemic conditions influence the periodontium. Diabetes mellitus (DM) is a prevalent metabolic disorder affecting nearly 90% of the world's population. It could be due to a defect in the secretion of insulin from beta-cells of the pancreatic islets of Langerhans, a defect in insulin action or a combination of both. Type 2 diabetes mellitus (T2DM) results from the body's ineffective use of insulin. Insulin resistance is a cardinal feature of T2DM. Diabetes is a risk factor for periodontal disease and there is strong evidence suggesting a two-way relationship between T2DM and periodontal disease; with diabetes increasing the risk of periodontal disease, and periodontal disease adversely affecting glycemic control [8].

The exact mechanism linking both conditions is still not yet fully understood, but it is believed that chronic hyperglycemia produces advanced glycation end products (AGEs) which bind to specific receptors on different cells such fibroblasts, macrophages and endothelial cells. As a result, macrophages are transformed into hyperactive cells that increase the production of inflammatory cytokines, tumour necrosis factor-alpha (TNF- α), and interleukins 1 β and 6 (IL-1 β , IL-6) which leads to periodontitis. Moreover, the production of AGEs increases the permeability and molecule adhesion in endothelial cells, while fibroblasts will show decreased collagen production which also contributes to periodontal disease. There is growing evidence supporting the fact that periodontal disease adversely affects glycemic control; it is now acknowledged that due to untreated periodontal disease, the systemic inflammatory burden may be increased in patients with DM. Due to this, they have an altered or delayed healing as compared to non-DM patients. There are relatively few studies that evaluate the adjunctive effect of LLLT in T2DM patients with periodontitis [9]. Therefore, this study sought to evaluate the effectiveness of LLL as an adjunct to non-surgical periodontal therapy (NSPT) in patients with T2DM, by observing changes in clinical parameters such as plaque index (PI), gingival index (GI), PD, and CAL.

2. MATERIALS AND METHODS

2.1 Study design

A randomized controlled cross-sectional study using a split-mouth design was planned. The study was approved by the local research and ethics committee; MOHP/RAK/SUBC/NO: 31-2017-UG-D. The study sample consisted of 10 patients aged 35-50 years diagnosed with periodontitis that were recruited from the Ras Al Khaimah College of Dental Sciences (RAKCODS) clinic, Ras Al Khaimah, United Arab Emirates. The sample was divided into two groups; Group 1: 5 Non-DM patients with periodontitis, and Group 2: 5 DM patients with periodontitis.

The inclusion criteria for Group 1 were (i) Non-DM patients diagnosed with Stage II Grade B periodontitis (ii) Presence of 4-5mm periodontal pockets on the mandibular 1st molars. For Group 2, the inclusion criteria were (i) T2DM patients diagnosed with Stage II Grade B periodontitis (ii) Presence of 4-5mm periodontal pockets on the mandibular 1st molars.

According to the 2017 World Workshop Classification of Periodontal and Peri-Implant Diseases, Stage II Grade B periodontitis patients were selected for this study, as these cases are of moderately progressing periodontitis with pocket depths of < 5mm and a clinical attachment loss of 2-3 mm and there were no teeth lost due to periodontal disease.

Although Glycated hemoglobin (HbA1c) blood levels were not obtained from the patients, they were asked if their blood glucose levels were controlled over the past 3 months, and all patients admitted that they had controlled levels (<7%). This was also confirmed

by the screening glucometer tests for average blood glucose levels performed just before the initiation of the treatment which had a range of (126-146mg/dl). A patient with average blood glucose levels <150mg/dl corresponds to <7% HbA1c levels [10,11]. The exclusion criteria for both groups were (i) Use of antibiotics or corticosteroid therapy 3 months before the study (ii) Patients with acute systemic illness (iii) Pregnant women (iv) Patients suffering from any hemorrhagic disorder or autoimmune disease (v) Smokers or tobacco chewers (vi) Patients who underwent periodontal treatment 3 months before the study.

All participants were given information about the study and informed consent was obtained from all participants.

2.2 Clinical examination

Clinical examination included measurements of Plaque Index (PI) (Silness and Loe), Gingival Index (GI) (Loe and Silness), Probing Depth (PD), and Relative Clinical Attachment Level (RCAL).

Acrylic stents were fabricated to be used to standardize the probe angulation and as a fixed reference point (Fig.1a).

PD and RCAL were measured using acrylic stents on the mesial, mid buccal and distal surfaces of the mandibular 1st molars using the University of North Carolina (UNC-15) periodontal probe. Acrylic stents were used to ensure accurate measurements, reproducibility, as well as minimize errors while probing (Fig.1b).

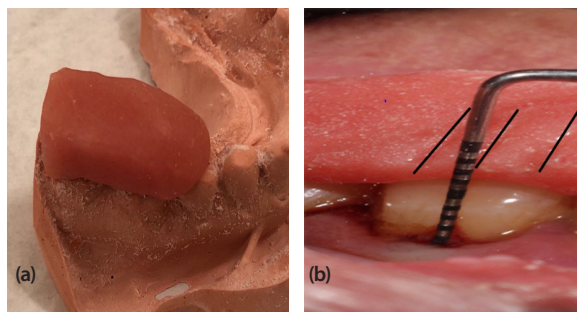


Figure 1. Acrylic stent (a), UNC-15 periodontal probe and acrylic stent in place with surface markings (b)

2.3 Treatment protocol

Patients in both groups received thorough clinical examination, oral hygiene instructions (OHI), full mouth scaling, polishing and root planning.

In each patient, the right and left mandibular first molars were then randomly allocated to either Control (SRP alone) or Test (SRP+LLLT) side.

A low-level diode laser "OPTODAN" (Scientific Development and Production Center "VEND", Saratov, Russia) with a 980 nm wavelength and a power setting of 13 mW was used in a continuous wave, non-contact mode with the help of a metallic knob delivery system having an optical diameter tip of 5 mm (Fig. 2a). The knob was used in a "brushstroke" motion on the gingival margin and attached gingiva of the buccal surface on the tooth (Fig. 2b).

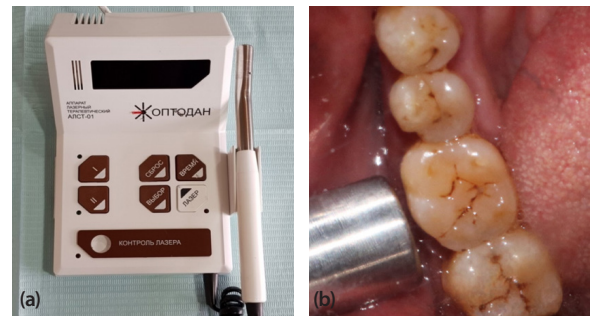

Figure 2. Low-level diode laser "OPTODAN" device (a), Positioning of the laser tip during application (b)

LLLT was applied to the test side on the 1st, 4th and 7th day respectively. On the first day, the laser application was for 2 minutes with an energy density of 8.2 J/cm². The second application, on day 4 was for 4 minutes delivering a total energy density of 16.4J/cm². The third application, on day 7 was for 5 minutes, with an energy density of 20.5J/cm². Re-evaluation of all clinical parameters was performed after 1 month of the laser therapy. The pain intensity felt by the patients during the treatment and 1 week postoperatively was determined with the help of a visual analogue scale (VAS), where the patients were told to rate the pain experienced on a scale of 0 to 10, with 0=no pain, 1-3=mild pain, 4-6=moderate pain, and 7-10=severe pain. Patients were on a maintenance protocol and given routine oral hygiene instructions. No antibiotics were prescribed post treatment, as they were not indicated in these cases since only non-surgical periodontal therapy was performed. Moreover, antibiotics can modify the oral flora and host response thereby altering the effect of LLLT by causing an ecological disturbance and inducing the selection of resistant strains as well as increasing their number, causing more amoxicillin resistant strains to be present [12].

2.4 Statistical analysis

The statistical significance of various periodontal indices that were elaborated between both groups was examined using the paired t-test. Using the following formula (postoperative index - preoperative index) the absolute change in every periodontal index at 1 month post-therapy about the baseline was calculated. The site with the deepest PD and RCAL in both groups was used to measure all parameters.

A p-value <0.05 was deemed statistically significant, and the valid data was analyzed using Statistical Package for the Social Sciences Statistics "SPSS Statistics" (International Business Machines Corporation "IBM", Chicago, IL, USA) for Microsoft Windows operating system (Microsoft Inc., Redmond, WA, USA).

3. RESULTS

The comparison of the mean values and change from day 0 to day 30 as well as standard deviation between parenthesis of PI, GI, PD, and RCAL in all patients within the test and control sides is described in Tab. 1.

Table 1. Test and Control Sides Comparison of Periodontal Parameters Studied (n=10)

Parameters	Test side (n=10)	Control side (n=10)	P-value	Significance
Plaque Index				
Day 0	1.20 (0.23)	1.22 (0.21)	0.806	NS
Day 30	0.17 (0.16)	0.48 (0.47)	0.078	NS
Change (Day 0-Day 30)	1.03 (0.25)	0.74 (0.50)	0.065	NS
Gingival Index				
Day 0	1.67 (0.47)	1.77 (0.60)	0.685	NS
Day 30	1.05 (0.15)	1.42 (0.31)	0.003	S
Change (Day 0-Day 30)	0.62 (0.43)	0.35 (0.54)	0.016	S
Probing Depth				
Day 0	4.50 (0.70)	5.00 (0.94)	0.196	NS
Day 30	3.60 (0.84)	5.00 (0.94)	0.003	S
Change (Day 0-Day 30)	0.90 (0.57)	0 (0)	0.001	S
RCAL*				
Day 0	9.70 (1.05)	9.40 (0.96)	0.517	NS
Day 30	8.80 (1.03)	9.40 (0.96)	0.196	NS
Change (Day 0-Day 30)	0.90 (0.57)	0 (0)	0.001	S

p<0.05= Significant (S), p>0.05= Not Significant (NS)

*Relative Clinical Attachment Level

The values of PI in the test side were 1.20±0.23 at baseline and 0.17±0.16 at 1 month, while the values in the control side were 1.22±0.21 at baseline and 0.48±0.47 at 1 month, so the differences were not statistically significant (p-value 0.806 and 0.078). Regarding the absolute change in the values of PI, the difference has shown no statistical significance either (p-value 0.065).

The GI has decreased from 1.67±0.47 to 1.05±0.15 in the test side and from 1.77±0.60 to 1.42±0.31 in the control side group after 1 month; the difference showed no statistical significance at baseline (p-value 0.685) but was statistically significant at 1 month (p-value 0.003). The difference shows statistical significance in the absolute change of the GI values as well (p-value 0.016).

With regard to the PD, there was a reduction from 4.50±0.70 mm to 3.60±0.84 mm in the test side at 1 month. The PD remained unchanged; 5.00±0.94 mm in the control side at 1 month, the difference was not statistically significant at baseline (p-value 0.196) and was statistically significant at 1 month (p-value 0.003). The difference in the absolute change in the values of PD was also statistically significant (p-value 0.001).

The RCAL was 9.70±1.05 and 9.40±0.96 mm in the test and control sides respectively at baseline; and at 1 month the RCAL was 8.80±1.03 and 9.40±0.96 mm in the test and control sides respectively. Therefore, no statistically significant gain in RCAL compared to

the baseline in the test and control sides (p-value 0.517 and 0.196), while the difference in the absolute change in the values of RCAL was statistically significant (p-value 0.001).

Tab. 2 demonstrates the comparison of VAS values on both sides. The differences between the test and control sides as well as the difference in the absolute change were all not statistically significant, either intraoperatively or postoperatively (p-value 1.000).

Table 2. Test and Control Sides Comparison of Visual Analogue Scale (VAS) (n=10)

Parameters	Test side (n=10)	Control side (n=10)	P-value	Significance
VAS				
Intraoperative	3.50 (1.26)	3.50 (1.26)	1.000	NS
1 week postoperative	1.40 (0.51)	1.40 (0.51)	1.000	NS
Change (1 week- intraoperative)	2.10 (0.88)	2.10 (0.88)	1.000	NS

p<0.05= Significant (S), p>0.05= Not Significant (NS)

3.1 Intergroup Comparison

Tab. 3 elucidates the comparison in the mean values and change from day 0 to day 30 as well as standard deviation of PI, GI, PD, and RCAL in the test side amongst both groups studied.

Table 2. Test Side Comparison of Periodontal Parameters Studied in Non-DM with Periodontitis and DM with Periodontitis Patients (n=5)

Parameters	Periodontitis Test side (n=5)	Periodontitis +DM Test side (n=5)	P-value	Significance
Plaque Index				
Day 0	1.20 (0.20)	1.20 (0.27)	1.000	NS
Day 30	0.15 (0.13)	0.20 (0.20)	0.667	NS
Change (Day 0-Day 30)	1.05 (0.21)	1.00 (0.31)	0.419	NS
Gingival Index				
Day 0	1.40 (0.37)	1.95 (0.41)	0.347	NS
Day 30	1.00 (0)	1.10 (0.22)	0.049	S
Change (Day 0-Day 30)	0.40 (0.38)	0.85 (0.38)	0.048	S
Probing Depth				
Day 0	4.40 (0.54)	4.60 (0.89)	0.681	NS
Day 30	3.20 (0.83)	4.00 (0.70)	0.141	NS
Change (Day 0-Day 30)	1.20 (0.45)	0.60 (0.55)	0.047	S
RCAL*				
Day 0	10.0 (1.41)	9.40 (0.54)	0.402	NS
Day 30	8.80 (1.48)	8.80 (0.44)	1.000	NS
Change (Day 0-Day 30)	1.20 (0.45)	0.60 (0.55)	0.047	S

p<0.05= Significant (S), p>0.05= Not Significant (NS)

*Relative Clinical Attachment Level

The mean values of PD and RCAL showed statistical improvement in non-DM patients with periodontitis compared to T2DM patients with periodontitis (p-value 0.047). The mean values of GI indicate a statistically significant improvement was obtained in T2DM patients with periodontitis post-therapy (p-value 0.049), with an absolute change of 0.85 compared to 0.40 in non-DM patients with periodontitis which was statistically significant as well (p-value 0.048).

4. DISCUSSION

The biostimulatory and bioinhibitory effects of laser are governed by the Arndt-Schultz law, which states that weak stimuli excite the biologic activity, while stronger stimuli will have an inhibitory effect. The treatment dose is probably the most important variable in laser treatment and should always be kept in mind when using PBM. If the anticipated response is not achieved then the clinician may need to re-evaluate the dose to ensure it is within the optimal range. The intended target for PBM treatments is to remain within the therapeutic window, which includes both biostimulatory and bioinhibitory effects [13].

In the present study, the treatment protocol was according to Prokhonchukov et al. [14].

The success of the periodontal treatment depends on the elimination of periodontal pathogens and their toxic byproducts from the dental root surface and periodontal soft tissue [15]. Currently, non-surgical periodontal therapy remains the “gold standard” of care to treat periodontal diseases [16,17]. However, patients with systemic conditions like DM demonstrate an altered or delayed healing. LLLT has shown to be effective in the treatment of impaired microcirculation, improves wound healing, pain relief, fracture healing, and reduction of inflammation as well as swelling [18,19,20]. Yet, there are a few articles about the study of LLLT in periodontal diseases in patients with DM. Therefore, we aimed to assess the adjunctive effects of LLLT with a diode laser in combination with SRP in T2DM patients with periodontitis.

Although not our primary objective, we compared the effect of the LLL on both test and control sides in all patients (n=10) in group 1 and group 2, which exhibited a significant improvement in GI, PD and RCAL on the test side (LLLT + SRP) when compared to the control side (SRP alone) at 1 month. A VAS was used to determine pain perception by the patients intraoperatively and 1 week post-operatively. There was no statistically significant difference between the control and test sides in both groups, which indicates that the level of discomfort was similar in both groups. There was no statistically significant difference in PI and VAS when comparing the control and test sides for both groups after 1 month. In a systematic review and meta-analysis on the PBM effect of LLL in the non-surgical treatment of periodontitis patients, Ren et al. found that LLLT-mediated SRP resulted in a significant improvement in PD and levels of IL-1 β in the gingival crevicular fluid compared with SRP alone in the short term [21]. There are a lot of studies where the adjunctive application of LLLT with SRP has shown to improve

BOP and inflammation in periodontitis patients as compared to basic periodontal therapy alone [22]. Most of the studies on LLLT as an adjunct to SRP have recorded and evaluated short-term outcomes demonstrating positive effects overall. However, researchers have still not been able to reach a specific treatment protocol [23].

The adjunctive application of LLLT in periodontitis patients with systemic conditions or diseases is able to modify the course of periodontal therapy. Upon comparison of the change (Day 0 - Day 30) in the test side (LLLT+SRP) of both groups, non-DM patients (Group 1) showed statistically significant improvement in PD and RCAL post-therapy as compared to T2DM patients (Group 2), while there was a statistically significant improvement in GI in T2DM patients (Group 2) as compared to non-DM patients (Group 1). Obradovic et al. studied the effect of LLLT on gingival inflammation using the GI by Loe & Silness; they concluded that LLLT is efficient in gingival inflammation elimination and can be proposed as an adjunctive tool in basic periodontal therapy of DM patients [24]. He performed another histological study in 2013, where he found that LLLT expressed healing and is evident by the absence of inflammatory cells. Tissue edema could not be seen and the number of blood vessels was reduced. In the gingival lamina propria, pronounced collagenization and homogenization were present. They then concluded that LLLT showed efficacy in the treatment of periodontitis in DM patients. Because of the more pronounced alterations of the periodontium in DM, the use of LLLT is of particular importance [7].

Demirturk-Goegun et al. found the additional benefit of the LLLT as an adjunct to SRP on gingival bleeding, but did not find any significant improvement on other clinical parameters [25].

Al-Sharif et al. stated that the mean values of GI, PI, and PD reduced significantly after-treatment of the two groups; SRP and SRP with laser groups. However, the SRP with laser group gained a greater reduction in the measured parameters in DM patients with periodontitis [26].

Seda et al. in their randomized controlled trial concluded that the adjunctive use of LLLT with NSPT in DM patients have positively affected the clinical and biochemical parameters, which was similar to the results of our study [27].

5. CONCLUSION

Within the limitations of this study, LLLT being used as an adjunct in periodontal therapy reduced gingival inflammation, decreased probing depth, and improved clinical attachment level. Non-DM patients with periodontitis had statistically significant improvement in both PD and RCAL, while DM patients with periodontitis had statistically significant improvement in GI only. Moreover, other parameters demonstrated strong correlation, yet no statistically significant result was reached. Most likely, this is due to the small sample size and short follow-up periods.

6. RECOMMENDATION

The efficacy of LLLT on periodontal pockets in DM patients is promising. Future randomized controlled

clinical trials with larger sample sizes and longer follow-up periods are highly recommended to assess the extent and effectiveness of LLLT as an adjunct to NSPT in DM patients.

7. LIMITATION OF THE STUDY

This study was performed during the COVID-19 pandemic. The sample size is relatively small because of the strict selection criteria applied and the limited number of patient flow to the students' clinic because of the COVID-19 restrictions. Also, the study had to be completed before end of May; the end of the academic year.

CONFLICT OF INTEREST

All authors declare that there is no financial/personal interest or belief that could affect their objectivity.

ETHICAL APPROVAL

The study was approved by the Research and Ethics Committee, UAE: MOHP/RAK/SUBC/NO: 31-2017-UG-D.

REFERENCES

- Cronshaw M, Parker S, Bordin-Aykroyd S, Lynch E. Photobiomodulation therapy and periodontitis: a discussion paper. *Cronicon EC Dent Sci.* 2019;18(8):1791-1797. [Google Scholar](#)
- Könönen E, Gursoy M, Gursoy UK. Periodontitis: a multifaceted disease of tooth-supporting tissues. *J Clin Med.* 2019 Jul 31;8(8):1135. doi: 10.3390/jcm8081135. PMID: 31370168; PMCID: PMC6723779. [Full text links PubMed Google Scholar](#)
- Murakami S, Mealey BL, Mariotti A, Chapple ILC. Dental plaque-induced gingival conditions. *J Periodontol.* 2018 Jun;89 Suppl 1:S17-S27. doi: 10.1002/JPER.17-0095. PMID: 29926958. <https://doi.org/10.1002/JPER.17-0095> [Full text links CrossRef PubMed Google Scholar WoS](#)
- Tawfig A, Abdullah A, Madani Y, et al. The Effect of Laser Therapy on Pocket Depth Reduction in Chronic Periodontitis Patients. *Cronicon EC Dent Sci.* 2017;16(1):6-16. [Google Scholar](#)
- Everett JD, Rossmann JA, Kerns DG, Al-Hashimi I. Laser assisted non-surgical periodontal therapy: a double blind, randomized clinical trial. *Open Dent J.* 2017 Feb 14;11:79-90. doi: 10.2174/1874210601711010079. PMID: 28357001; PMCID: PMC5345326. <https://doi.org/10.2174/1874210601711010079> [Full text links CrossRef PubMed Google Scholar Scopus WoS](#)
- Mishra A, Shergill N. The effect of low-level laser therapy on nonsurgical periodontal therapy: a clinico-biochemical study. *Journal of Dental Lasers.* 2018 Jan 1;12(1):14. https://doi.org/10.4103/jdl.jdl_19_17 [CrossRef Google Scholar](#)
- Obradović R, Kesić L, Mihailović D, et al. A histological evaluation of a low-level laser therapy as an adjunct to periodontal therapy in patients with diabetes mellitus. *Lasers Med Sci.* 2013 Jan;28(1):19-24. doi: 10.1007/s10103-012-1058-7. Epub 2012 Feb 5. PMID: 22311659. <https://doi.org/10.1007/s10103-012-1058-7> [Full text links CrossRef PubMed Google Scholar Scopus WoS](#)
- Wu CZ, Yuan YH, Liu HH, et al. Epidemiologic relationship between periodontitis and type 2 diabetes mellitus. *BMC Oral Health.* 2020 Jul 11;20(1):204. doi: 10.1186/s12903-020-01180-w. PMID: 32652980; PMCID: PMC7353775. <https://doi.org/10.1186/s12903-020-01180-w> [Full text links CrossRef PubMed Google Scholar Scopus WoS](#)
- Lalla E, Lamster IB, Drury S, et al. Hyperglycemia, glycoxidation and receptor for advanced glycation endproducts: potential mechanisms underlying diabetic complications, including diabetes-associated periodontitis. *Periodontol 2000.* 2000 Jun;23:50-62. doi: 10.1034/j.1600-0757.2000.2230104.x. PMID: 11276765. <https://onlinelibrary.wiley.com/doi/abs/10.1034/j.1600-0757.2000.2230104.x> [Full text links CrossRef PubMed Google Scholar Scopus WoS](#)
- Papapanou PN, Sanz M, Buduneli N, et al. Periodontitis: Consensus report of workgroup 2 of the 2017 World Workshop on the Classification of Periodontal and Peri-Implant Diseases and Conditions. *J Periodontol.* 2018 Jun;89 Suppl 1:S173-S182. doi: 10.1002/JPER.17-0721. PMID: 29926951. <https://doi.org/10.1002/JPER.17-0721> [Full text links CrossRef PubMed Google Scholar Scopus WoS](#)

PATIENTS CONSENT

All participants were informed about the clinical procedure of the study and willingly signed the informed consent.

FUNDING

This study was not funded.

STATEMENT OF HUMAN RIGHTS

This study was conducted in accordance with the 1964 Declaration of Helsinki and its subsequent amendments.

ACKNOWLEDGMENTS

We would like to thank the clinical staff of the RAK College of Dental Sciences for the continuous support and help while conducting this research.

AUTHOR CONTRIBUTIONS

FAH: background writing, clinical work, preparation of results and manuscript. **HZ:** study design, background review, results.

JD: clinical work, results, discussion. **WH:** background writing, clinical work, preparation of results. **OAJ:** statistical analysis, preparation of results. **JAK:** study design, result writing, review of the discussion, overall writing up, preparation of the manuscript.

- Tonetti MS, Greenwell H, Kornman KS. Staging and grading of periodontitis: Framework and proposal of a new classification and case definition. *J Periodontol.* 2018 Jun;89 Suppl 1:S159-S172. doi: 10.1002/JPER.18-0006. Erratum in: *J Periodontol.* 2018 Dec;89(12):1475. PMID: 29926952. <https://doi.org/10.1002/JPER.18-0006> [Full text links CrossRef PubMed Google Scholar Scopus WoS](#)
- Khalil D, Hultin M, Rashid MU, Lund B. Oral microflora and selection of resistance after a single dose of amoxicillin. *Clin Microbiol Infect.* 2016 Nov;22(11):949.e1-949.e4. doi: 10.1016/j.cmi.2016.08.008. Epub 2016 Aug 26. PMID: 27569711. <https://doi.org/10.1016/j.cmi.2016.08.008> [Full text links CrossRef PubMed Google Scholar Scopus WoS](#)
- Ross G, Ross A. Photobiomodulation : an invaluable tool for all dental specialties. *J Laser Dent.* 2009;17(3):117-124. [Google Scholar](#)
- Prokhonchukov AA, Zhizhina NA, Pozharitskaia MM, et al. [Possibilities and prospects of the dental apparatus Optodan use for the magnetic-laser treatment of stomatologic diseases]. *Stomatologiya (Mosk).* 2006;85(2):68-72. Russian. PMID: 16710285.
- Giannelli M, Formigli L, Lorenzini L, Bani D. Combined photoablative and photodynamic diode laser therapy as an adjunct to non-surgical periodontal treatment: a randomized split-mouth clinical trial. *J Clin Periodontol.* 2012 Oct;39(10):962-970. doi: 10.1111/j.1600-051X.2012.01925.x. Epub 2012 Jul 27. PMID: 22834932. <https://doi.org/10.1111/j.1600-051X.2012.01925.x> [Full text links CrossRef PubMed Google Scholar Scopus WoS](#)
- Lai SM, Zee KY, Lai MK, Corbet EF. Clinical and radiographic investigation of the adjunctive effects of a low-power He-Ne laser in the treatment of moderate to advanced periodontal disease: a pilot study. *Photomed Laser Surg.* 2009 Apr;27(2):287-293. doi: 10.1089/pho.2007.2206. PMID: 18785848. <https://doi.org/10.1089/pho.2007.2206> [Full text links CrossRef PubMed Google Scholar Scopus WoS](#)
- Nagarakanti S, Gunupati S, Chava VK, Reddy BV. Effectiveness of subgingival irrigation as an adjunct to scaling and root planing in the treatment of chronic periodontitis: a systematic review. *J Clin Diagn Res.* 2015 Jul;9(7):ZE06-9. doi: 10.7860/JCDR/2015/13862.6210. Epub 2015 Jul 1. PMID: 26393230; PMCID: PMC4573063. <https://doi.org/10.7860/JCDR/2015/13862.6210> [Full text links CrossRef PubMed Google Scholar Scopus WoS](#)
- Hagiwara S, Iwasaka H, Okuda K, Noguchi T. GaAlAs (830 nm) low-level laser enhances peripheral endogenous opioid analgesia in rats. *Lasers Surg Med.* 2007 Dec;39(10):797-802. doi: 10.1002/lsm.20583. PMID: 18081143. <https://doi.org/10.1002/lsm.20583> [Full text links CrossRef PubMed Google Scholar WoS](#)
- Obradović RR, Kesić LG, Pesevska S. Influence of low-level laser therapy on biomaterial osseointegration: a mini-review. *Lasers Med Sci.* 2009 May;24(3):447-451. doi: 10.1007/s10103-008-0573-z. Epub 2008 Jun 20. PMID: 18566853. <https://doi.org/10.1007/s10103-008-0573-z> [Full text links CrossRef PubMed Google Scholar Scopus WoS](#)
- Reddy GK. Photobiological basis and clinical role of low-intensity lasers in biology and medicine. *J Clin Laser Med Surg.* 2004 Apr;22(2):141-150. doi: 10.1089/104454704774076208. PMID: 15165389. <https://doi.org/10.1089/104454704774076208> [CrossRef PubMed Google Scholar Scopus](#)

21. Ren C, McGrath C, Jin L, et al. The effectiveness of low-level laser therapy as an adjunct to non-surgical periodontal treatment: a meta-analysis. *J Periodontol Res*. 2017 Feb;52(1):8-20. doi: 10.1111/jre.12361. Epub 2016 Mar 2. PMID: 26932392; PMCID: PMC5297978. <https://doi.org/10.1111/jre.12361>
[Full text links](#) [CrossRef](#) [PubMed](#) [Google Scholar](#) [Scopus](#) [WoS](#)

22. Mastrangelo F, Dedola A, Cattoni F, et al. Etiological periodontal treatment with and without low-level laser therapy on IL-1 β level in gingival crevicular fluid: an in vivo multicentric pilot study. *J Biol Regul Homeost Agents*. 2018 Mar-Apr;32(2):425-431. PMID: 29577710. [PubMed](#) [Google Scholar](#) [Scopus](#)

23. Gholami L, Asefi S, Hooshyarfard A, et al. Photobiomodulation in periodontology and implant dentistry: part 1. *Photobiomodul Photomed Laser Surg*. 2019 Dec;37(12):739-765. doi: 10.1089/pho-2019.4710. Epub 2019 Nov 21. PMID: 31750783. <https://doi.org/10.1089/pho-2019.4710>
[Full text links](#) [CrossRef](#) [PubMed](#) [Google Scholar](#)

24. Obradović R, Kesić L, Jovanović G, et al. [Low power laser efficacy in the therapy of inflamed gingivae in diabetics with parodontopathy]. *Vojnosanit Pregl*. 2011 Aug;68(8):684-689. Serbian. doi: 10.2298/vsp1108684o. PMID: 21991792. <https://doi.org/10.2298/vsp1108684o>

25. Demirturk-Gocgun O, Baser U, Aykol-Sahin G, et al. Role of low-level laser therapy as an adjunct to initial periodontal treatment in type 2 diabetic patients: a split-mouth, randomized, controlled clinical trial. *Photomed Laser Surg*. 2017 Feb;35(2):111-115. doi: 10.1089/pho.2016.4117. Epub 2016 Nov 17. PMID: 27855270. <https://doi.org/10.1089/pho.2016.4117>
[Full text links](#) [CrossRef](#) [PubMed](#) [Google Scholar](#) [Scopus](#) [WoS](#)

26. Al-Sharif FM, Al-Jiffri SO. Impact of laser therapy added to non-surgical therapy in non-insulin dependent diabetic Saudi patients with chronic periodontitis. *J Dent Health Oral Disord Ther*. 2019;10(6):338-342. DOI: 10.15406/jdhodt.2019.10.00508. <https://doi.org/10.15406/jdhodt.2019.10.00508>
[CrossRef](#) [Google Scholar](#)

27. Özberk SS, Gündoğar H, Özkaya M, et al. The effect of photobiomodulation therapy on nonsurgical periodontal treatment in patients with type 2 diabetes mellitus: a randomized controlled, single-blind, split-mouth clinical trial. *Lasers Med Sci*. 2020 Mar;35(2):497-504. doi: 10.1007/s10103-019-02897-z. Epub 2019 Oct 23. PMID: 31641967. <http://doi.org/10.1007/s10103-019-02897-z>
[Full text links](#) [CrossRef](#) [PubMed](#) [Google Scholar](#) [WoS](#)

CV

Dr. Fares Al Hajeb, a dedicated general dentist who is passionate about evidence-based dentistry as well as devoted to keeping up to date with the latest research in the dental field; he graduated from the RAK College of Dental Sciences in 2020 and completed his one year Internship program at Healthpoint Hospital in early 2022. He practices as a GP Dentist in the private sector in Abu Dhabi, UAE.

The main contribution in this study was to find and adhere to the strict selection criteria of patients during the COVID-19 pandemic as well as the complete clinical workflow and result preparation after data interpretation of an adjunctive measure to treat periodontitis in both DM and non-DM patients by incorporating a low level laser therapy.

Fares Al HAJEB

BDS, Intern
 Department of Dentistry
 Healthpoint Hospital
 Mubadala Health
 Abu Dhabi, UAE



Questions

1. In periodontitis, the inflammatory cytokines, such as TNF- α , IL6 and IL 1 β are thought to be released by which of the following cells?

- a. T-Lymphocytes;
- b. Mast cells;
- c. Neutrophils;
- d. Macrophages.

2. Which of the following activities is/are associated with the use of Low-level laser in the treatment of periodontitis?

- a. Increase the phagocytosis process;
- b. Increase in cellular repair and healing;
- c. Promotes local hemostasis;
- d. Reduces glycemia.

3. When using photobiomodulation, which of the following laws govern the biostimulatory and bioinhibitory effects of a low level laser?

- a. Arndt-Shultz Law;
- b. Newton's Law;
- c. Snell's Law;
- d. Beer-Lambert Law.

4. What is the typical wavelength range for a diode laser used?

- a. 1500-2000 Nm;
- b. 2900-3000 Nmt;
- c. 600-1100 Nm;
- d. 500-550 Nm.

MANDIBULAR INCISOR INCLINATION IN PATIENTS WITH CLASS II MALOCCLUSION: COMPARISON OF TREATMENT EFFECTS THROUGH TIME

Anastasia Tsolaki^{1a} , Maria Tsami^{2b} , Athina Chatzigianni^{3c} , Moschos A. Papadopoulos^{3d*} 

¹Health Professions Division, Department of Orthodontics, College of Dental Medicine, Nova Southeastern University, FL, USA

²Private practice, Larissa, Greece

³Department of Orthodontics, School of Health Sciences, Faculty of Dentistry, Aristotle University of Thessaloniki, Thessaloniki, Greece

^aPostgraduate Student; e-mail: anastasia.tsolaki96@gmail.com; ORCIDiD: <https://orcid.org/0009-0005-9856-8140>

^bDentist; e-mail: mlilly@hotmail.com; ORCIDiD: <https://orcid.org/0009-0001-8481-0128>

^cAssistant Professor; e-mail: achatzianni@dent.auth.gr; ORCIDiD: <https://orcid.org/0000-0001-7114-689X>

^dProfessor and Head; e-mail: mikepap@dent.auth.gr; ORCIDiD: <https://orcid.org/0000-0002-7630-7258>

ABSTRACT

 [https://doi.org/10.25241/stomaedu.2022.9\(3-4\).art.3](https://doi.org/10.25241/stomaedu.2022.9(3-4).art.3)

Introduction The aim of this study was to evaluate the effect of different treatments on lower incisor (L1) inclination in patients with Class II malocclusion.

Methodology 73 patients (39 females, 34 males) with Class II malocclusion were retrospectively collected from the postgraduate orthodontic clinic. All patients were treated at least with multibracket appliance (MBA) and Class II elastics (CLII) alone (control group), or in combination with the removable-functional appliance (RFA), fixed-functional appliance (FFA), or lingual arch (LA). Pre- and post-treatment L1-NB (mm), L1-GoGn (°) and L1-NB (°) values were analyzed. The analysis of the treatment effect in relation to the outcomes and time were done by the Propensity Score Matching (PSM) method using Cox regression and Survival analysis.

Results Regarding L1-NB distance, patients treated only with CLII elastics have lower risk of incisor proclination, however, the risk may occur from the beginning of the treatment. FFA, RFA and LA present higher risk of incisor proclination, but this occurs later in time (hazard ratio HR= 0.4 RFA/0.22 FFA and LA). Concerning L1-GoGn angle, all treatments have high risk of proclination. However, RFA reduces the rate of risk (p=0.003) (HR=0.22), while FFA increases the rate of risk (HR=0.35).

Conclusion Multibracket orthodontic treatment with CLII elastics alone produces unfavorable labial incisor inclination rapidly. Combination treatment of RFA with CLII elastics delays the occurrence of proclination, while FFA highly increases the risk of proclination. The use of the lingual arch retains the position of the dentition for longer time, however once the lower incisor proclination occurs, it deteriorates fast.

KEYWORDS

Mandibular Incisor; Inclination; Class II Malocclusion


1. INTRODUCTION

From the early steps in orthodontic science, the position and inclination of the lower incisor has been considered essential in diagnosis, treatment planning and retention. In 1941 Holly Broadbent correlated normal dentofacial growth with incisor mandibular plane angle and set the basis for cephalometric analysis [1]. In 1943 Margolis was the first to correlate lower incisor inclination with chin position [2]. Tweed advocated that the mandibular incisors must always be positioned upright on the alveolar process in order to achieve harmony in the lower facial third [3].

Class II malocclusion is present in approximately one-third of the patients seeking orthodontic treatment [4]. Correction of Class II discrepancies

is achieved with a variety of extraction and non-extraction approaches, maxillary expansion, use of headgears, functional appliances, fixed-functional appliances, Class II elastics, with or without skeletal anchorage and other [5].

Systematic reviews (SRs) and meta-analyses (MAs) in Class II malocclusion patients treated with removable functional appliances revealed minor skeletal changes, while the effects of the treatment were mostly dentoalveolar, such as increased inclination of lower incisors and uprighting of the maxillary incisors [6-7]. Because the lack of success of functional appliances has been attributed under some circumstances to the lack of patient compliance regarding appliance wear, the treatment effects of fixed functional appliances (FFAs) were examined as well in other SRs or/and MAs and presented with

 **OPEN ACCESS** This is an Open Access article under the CC BY-NC 4.0 license.

Peer-Reviewed Article

Citation: Tsolaki A, Tsami M, Chatzigianni A, Papadopoulos AM. Mandibular incisor inclination in patients with class II malocclusion: comparison of treatment effects through time. *Stoma Edu J.* 2022;9(3-4):95-102.

Received: January 02, 2022; **Revised:** March 17, 2022; **Accepted:** March 28, 2022; **Published:** March 30, 2022.

***Corresponding author:** Prof. Moschos A. Papadopoulos; Department of Orthodontics, School of Health Sciences, Faculty of Dentistry, Aristotle University of Thessaloniki, Thessaloniki, Greece; **Tel./Fax:** +302310999556; e-mail: mikepap@dent.auth.gr

Copyright: © 2022 the Editorial Council for the Stomatology Edu Journal.

similar results as far as the inclination of the lower incisors is concerned.

Further, the application of Class II elastics apart from the side effects that produces, such as extrusion of the lower first molars and of the upper incisors, their use is highly associated with proclination of the lower incisors and retroclination of the upper incisors [8].

A direct comparison of the effect of different therapeutic methods on lower incisor inclination seems not to have been examined thoroughly. Thus, the aim of this study was to evaluate the effect of different orthodontic treatment approaches taking also into consideration the possible influence of treatment time on the lower incisor inclination of patients presenting Class II discrepancy.

2. METHODOLOGY

A study sample of 73 patients (39 females and 34 males; mean age 13.2±4.1 years) was retrospectively collected in consecutive order from the Postgraduate Orthodontic Clinic. The patients' inclusion criterion was the Class II malocclusion with at least half cusp to full Class II canine and molar relationship and Class II treatment approach, such as functional appliance, Class II elastics and other. Patients with extractions, stripping, surgical intervention or craniofacial anomalies were excluded. All patients were treated at least with the multibracket appliance (MBA) (Straight wire, Roth prescription) in both dental arches and Class II elastics, with or without another treatment, which preceded or followed, such as removable-functional appliance (RFA), fixed-functional appliance (FFA), or lingual arch (LA).

The descriptive statistics of the sample are shown in Tab. 1. Pre-treatment and post-treatment lateral cephalograms were analyzed with the use of the Viewbox 4 software (dHal Software, Athens, Greece) to measure the inclination and position of the lower incisors at the beginning and at the end of the treatment. The angles between the lower incisor (L1) and the Nasion-B point line (L1-NB°), the Go-Gn

line (L1-GoGn°) and the distance between L1 and Nasion-B point line (L1-NB mm) were examined. The total treatment time and also the treatment time of each appliance was available from the patients' records. More specifically, the date of application of the MB, CLII, RFA, FFA or LA and the total active treatment of each appliance were retrieved. Also, crowding was evident in 35 patients (47,9%), while 38 patients (52,1%) had no crowding (Tab. 2).

Table 2. Descriptive statistics of the sample regarding the presence of crowding in the lower arch in the different treatment groups.

MBA+CLII		No other treatment	+ FFA	+ RFA	+ LA	Total
Crowdin	Yes	23	3	2	7	35
	No	16	7	15	0	38
Total		39	10	17	7	73

An analysis of the treatment effect in relation to the outcomes and the implementation of time was done by the propensity score matching (PSM) method using Cox regression and Survival analysis [9]. In randomized clinical trials (RCTs) treatment groups and/or control groups are balanced for the baseline characteristics of participants between groups with no systematic difference between them. With the use of PSM the differences between groups can be estimated and the distribution of the baseline characteristics can be balanced to be similar between the groups [10]. In the orthodontic field, orthodontic treatments are not static with a direct treatment effect. Instead, different types of treatments, appliances or methods are used during a long period of time and usually there are differences between a specific treatment effect and the time of application of the corresponding treatment. The treatment effect is affected by the time period of the treatment. The involvement of time in the orthodontic treatment effect can be studied and analyzed using two statistical tools, which are very common in medical science; the Survival analysis and the Cox regression analysis. Survival analysis is a statistical technique to analyze a "time to event outcome variable", where the

Table 1. Descriptive statistics of the sample. CLII Tx time: Time of Class II elastics wear during treatment; Total Tx Time: Total treatment duration; L1-NB (mm): distance between the lower incisor (L1) and Nasion-B point line; L1-GoGn°: angle between L1 and the Nasion-B point line; L1-GoGn: angle between L1 and the Go-Gn line.

Variable Treatment	N	Age Mean (±SD)	Sex Male %	CLII Tx Time Mean (±SD)	Total Tx Time Mean (±SD)	L1-NB (mm) Mean (±SD)	L1-NB (°) Mean (±SD)	L1-GoGn (°) Mean (±SD)
MBA + CLII	39	14.1 (±5.18)	46.15%	13 (±8.2)	37.6 (±16.3)	2.73 (±1.58)	25.5 (±6.44)	98.3 (±6.40)
MBA + CLII + FFA	10	13.8 (±1.93)	60%	11 (±10.9)	34.4 (±8)	4 (±2.43)	30.8 (±8.36)	107 (±8.44)
MBA + CLII + RFA	17	11.4 (±1.46)	47.06%	16.4 (±10.7)	48.6 (±16.1)	3.93 (±2.35)	28.3 (±6.03)	102 (±5.02)
MBA + CLII + LA	7	11.1 (±1.07)	71.42%	11.2 (±13.4)	47.7 (±19.9)	2.70 (±1.63)	26.8 (±8.15)	99.7 (±9.08)

outcome variable are the treatments that have been used in a study and the event is the goal achievement of the treatment. The Cox (Proportional Hazards) regression is a statistical method for studying the effect of multiple variables upon the time an event takes to happen.

An important limitation of observational studies in relation to non-randomized study designs is the treatment selection bias. Due to that limitation, the baseline characteristics of the study population could dramatically differ for each treatment group [10-13]. Direct estimations about the treatment effect without considering these sources of heterogeneity can lead to bias estimations about the treatment effects [14]. Propensity score can be estimated by a logistic regression model that predicts the treatment assignment given the observed baseline characteristics. This method gives the opportunity to evaluate the treatments through relatively homogeneous population groups. It is worth mentioning that the considerable amount of differences in the sample size of the groups of this study is balanced with the use of PSM, which takes this inequality into account. For example, crowding differences between patient groups were balanced with the use of different statistical weights among groups. Randomized clinical trials are the goal standard for estimating casual effectiveness by assigning treatments independently from covariates. The process of propensity score simulates the process of RCTs with the limitation that the unobserved confounders have no way to be adjusted [15].

3. RESULTS

First the Propensity Score of the 73 patients was computed with the Average Treatment Effect (ATE) method to compare outcomes among the treatments. Treatment outcomes were categorized into "accepted" or "not accepted" according to the value of the outcome and the relationship with the physiological mean values. More specific, the value of outcome is referred to the post-treatment value of the lower incisor inclination. Accepted outcomes had a post-treatment incisor inclination value within the mean \pm Standard Deviation (SD) value of each measurement, while not accepted outcomes lay beyond the SD values and exceeded the mean value. The ATE method was also used to compute Propensity Scores for the population and a Cox proportional hazard model was implemented to assess the impact of the treatments on the above outcomes. The group of patients treated with MBA/Class II elastics and no other treatment were used as reference group to estimate the effect of the other treatments. For the above method we had two groups of patients, those who had an accepted outcome (normal lower incisor inclination) and those who had a non-accepted outcome (lower incisor proclination), according to the post-treatment incisor inclination value.

3.1 Patients with an accepted outcome

Patients with an accepted outcome presented an accepted post-treatment lower incisor inclination

value. Tab. 3 and Figs. 1, 2, 3 show the results of the Cox regression analysis.

Table 3. Prognostic performance of different treatments on the lower incisor inclination for the accepted outcome (post-treatment normal incisor inclination) after adjusting with ATT Propensity Score.

Treatments/Outcomes		L1-NB (mm)	L1-NB (°)	L1-GoGN (°)
FFA	Coef	-1.15	-1.48	-1.12
	Hazard Ratio (CI)	0.31 (0.07-1.41)	0.23 (0.02-2.07)	0.32 (0.04-2.46)
	p value	0.1312	0.36	0.276
RFA	Coef	-3.39	-2.71	-0.98
	Hazard Ratio (CI)	0.03 (0.003-0.33)	0.07 (0.01-0.31)	0.37 (0.05-2.69)
	p value	0.00371**	0.000618***	0.260
LA	Coef	-1.37	1.77	-1.62
	Hazard Ratio (CI)	0.25 (0.05-1.29)	0.17 (0.01-2.88)	0.2 (0.01-3.32)
	p value	0.09813	0.22	0.12

*p<0.05, **p<0.01

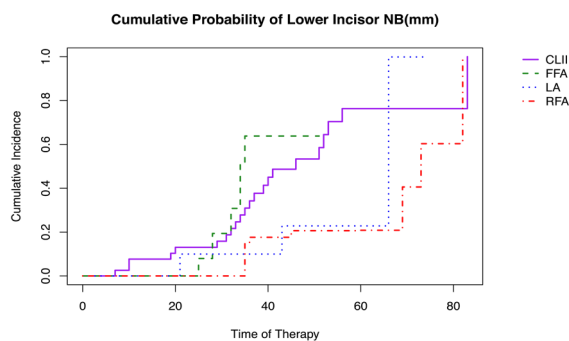


Figure 1. Reverse Kaplan-Meier is presented for the cumulative probability of Lower Incisor NB (mm) for the endpoint with normal inclination.

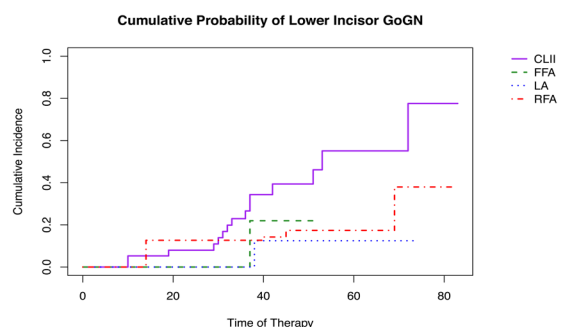


Figure 2. Reverse Kaplan-Meier is presented for the cumulative probability of Lower Incisor-GoGN angle for the endpoint with normal inclination.

The analysis showed that RFA treatment results in a statistically significant achieve effect of L1-NB (mm) and the L1-NB (°) ($p=0.00371$ and 0.000618 respectively). The negative sign of the regression coefficient (coef) in the tables shows that the probability of each additional treatment to reach the desired accepted result for every outcome reduces the effect of Class II elastics. For example, regarding the L1-NB (mm) value, the RFA treatment decreases the cumulative probability of producing an accepted

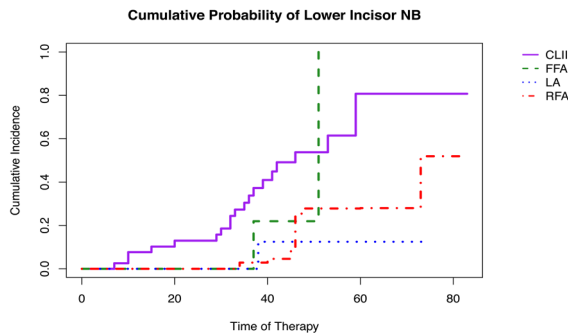


Figure 3. Reverse Kaplan-Meier is presented for the cumulative probability of Lower Incisor-NB angle for the endpoint with normal inclination.

3.2 Patients with a non-accepted outcome

Patients with a non-accepted outcome presented a non-accepted post-treatment lower incisor inclination value. Further analysis was conducted in this group of patients and these were the most important results. Specifically, the Average Treatment Effect on the Treated (ATT) Propensity Score was computed for the group who exceeded the accepted values and presented incisor proclination. Survival analysis was conducted to examine the risk of labial incisor inclination among the different treatments. Regarding the L1-NB (mm) measurement, according to the Kaplan-Meier graph (Fig. 4) patients treated only with CLII have lower risk of exceeding the L1-NB

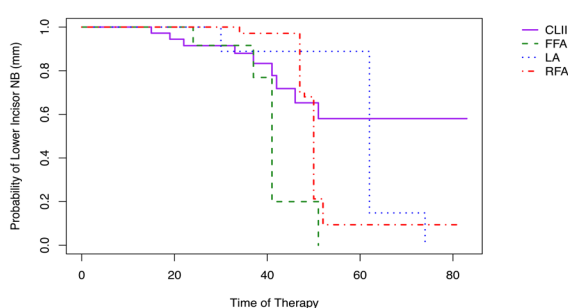


Figure 4. Kaplan-Meier curve is presented for patients with Lower Incisor-NB (mm) for the proclined endpoint.

However, this risk may occur from the beginning, during the first weeks of application of the Class II elastics. On the other hand, RFA, FFA, and LA present a higher risk of producing a not accepted outcome of the L1-NB (mm) value compared to CLII alone during the treatment, but this happens later in time than the CLII. Moreover, RFA causes a not accepted L1-NB (mm) value in a later time compared to all the other treatments.

Specifically, RFA has a higher rate of increasing the probability of lower incisor proclination with a hazard ratio of 0.4 compared to FFA and LA, which have a hazard ratio of 0.22. This means that once the risk occurs, RFA can deteriorate the L1-NB (mm) value in a shorter time period.

Regarding the L1-GoGn (°) measurement, according to the Kaplan-Meier graph (Fig. 5) patients treated with CLII, RFA, FFA and LA have all high risk of producing lower incisor proclination.

Likewise, for CLII alone treatment the risk may occur from the beginning, during the first weeks of application of the Class II elastics. In contrast, RFA, FFA and LA have the probability to produce the

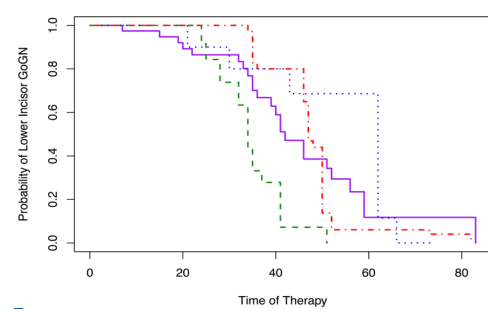


Figure 5. Kaplan-Meier curve is presented for patients with Lower Incisor-GoGn angle with proclined endpoint.

Especially the RFA treatment reduces the rate of risk with a statistical significance of $p=0.00269$ compared to the other treatments, with a hazard ratio of 0.22. On the other hand, FFA has an increased rate of risk for proclination with a hazard ratio of 0.35.

Lastly, regarding the L1-NB (°) measurement, according to the Kaplan-Meier graph (Fig. 6) patients treated with CLII, RFA, FFA and LA have all again high

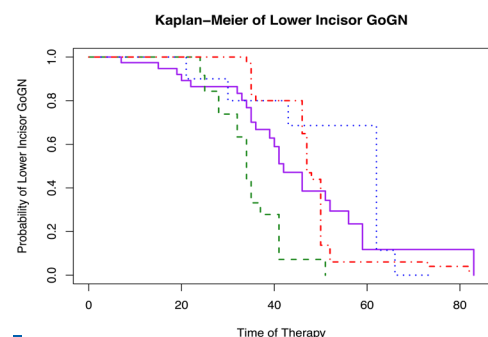


Figure 6. Kaplan-Meier curve is presented for patients with Lower Incisor-NB angle with proclined endpoint.

The risk for labial inclination is the same as for L1-GoGn (°) measurement. RFA reduces the rate of risk with a statistical significance of $p=0.0465$ compared to the other treatments, with a hazard ratio of 0.3. FFA on the other hand has an increased rate of risk for increasing lower incisor inclination with a hazard ratio of 0.5.

As above, only the combination of CLII with FFA increases the probability of proclination, while the combination with RFA and LA seems to reduce the probability of risk of proclination.

As for the treatment time, CLII alone produces unfavorable treatment effects more rapidly compared to all combinations. Table 4 shows the effect sizes of survival analysis.

Table 4. Prognostic performance of treatments for L1-NB (mm), L1-NB (°), L1-GoGN (°) for the not accepted outcome (post-treatment lower incisor proclination) after adjusting with ATT Propensity Score.

Treatments/Outcomes		L1-NB (mm)	L1-NB (°)	L1-GoGN (°)
FFA	Coef Hazard Ratio (CI)	-1.5 0.22 (0.03-1.61)	-0.68 0.5 (0.12-2.17)	-1.06 0.35 (0.08-1.5)
	p value	0.137	0.36	0.157
	Coef Hazard Ratio (CI)	-0.9 0.4 (0.06-2.52)	-1.2 0.3 (0.09 - 0.98)	-1.51 0.22 (0.08-0.59)
RFA	p value	0.333	0.0465	0.00269**
LA	Coef Hazard Ratio (CI)	-1.5 0.22 (0.02-3.12)	0.87 0.42 (0.11-1.56)	-1.08 0.34 (0.09-1.33)
	p value	0.265	0.19	0.12

*p<0.05, **p<0.01

3.3 Treatment time

It is worth mentioning that the treatment time of the CLII elastics wear was studied separately for each combination treatment, so as to determine whether the treatment time of the CLII elastics in the combined treatments with other appliances affects the final outcome. After the statistical analysis it appeared that the treatment time of CLII elastics in the combination treatments does not affect statistically significant the outcome (p-values of 0.765, 0.907, 0.498 for lower incisor NB, lower incisor NB (mm) and lower incisor GoGn respectively).

4. DISCUSSION

TAs already known, studies comparing dentoskeletal alterations in treated Class II patients with those of untreated subjects, revealed significant retroclination of maxillary incisors and protrusion and proclination of lower incisors [16-18].

Despite the limitation of this study regarding the considerable amount of differences in the sample size of the groups, the use of the PSM method, which takes into account those differences, seemed to have clearly depicted the probability of risk for lower incisor proclination between the investigated treatment approaches.

The use of intermaxillary elastics is well documented in the literature, which claims that they are effective in correcting the anteroposterior relationship of the dentition, although undesirable side effects can occur [19-22]. Most authors mention adverse results from the horizontal vector of force, which has been shown to rotate or mesially tip the mandibular first molars, procline the mandibular anterior teeth, and displace the entire lower dental arch anteriorly [19,21,23,24]. Systematic reviews revealed that

Class II elastics are effective in correcting class II malocclusions and that their effects are primarily dentoalveolar, such as flaring of mandibular incisors and loss of mandibular anchorage. In this study it was evident that multibracket appliance with Class II elastics treatment is associated with the highest risk of lower incisor proclination compared to the other treatments under investigation.

To overcome the lower incisor proclination side effect, different types of appliances have been proposed to reinforce the anchorage in the molar region and thus, overcome the mandibular dental side effects. For example, the development of the lingual arch is attributed to the efforts of Lloyd S. Lourie [25] and John V. Mershon [26]. It is considered that the lingual arch can resolve lower incisor crowding by maintaining the arch perimeter [27]. The aim of including the lingual arch in the treatment of Class II malocclusion is mostly to enhance mandibular anchorage and minimize the side effects of Class II elastics, such as molar rotation and lingual tipping and protrusion of mandibular incisors [28]. In this study it was confirmed that the use of the lingual arch, when used with MBA and Class II elastics can retain the mandibular incisors for a longer period of time compared to MBA and Class II elastics alone. This means that the lingual arch retains the probability of risk for a longer period of time, meaning that the lower incisors may remain stable during treatment before reaching the not accepted proclined endpoint. However, once the risk with the use of LA occurs, then the incisors may deteriorate fast. Concluding, there is a timepoint after which the lower incisor inclination may deteriorate very fast and abruptly when lingual arch and Class II elastics are used.

A lot of studies have been conducted in order to evaluate the skeletal and dental changes that account for the Class II correction in subjects treated with Class II elastics compared with subjects treated with removable or fixed functional appliances [29-31]. These studies suggested that either there was no statistically significant difference between the two treatment modalities or if there was any, it did not last in the long term [32]. These results indicate that the final outcome of the treatment of Class II malocclusion might be similar independently of the orthodontic device used.

However, the risks of incisor proclination varied among treatments at this study. Compared to the use of MB and CLII alone, only the combination of MB and CLII with FFA increases the probability of incisor proclination, while the combination of MB and CLII with RFA or LA seems to reduce the probability of risk of proclination. This probably means that the use of RFA reduces the total time of Class II elastics wear, leading to more favorable results.

Systematic reviews and meta-analysis concluded that the treatment of Class II malocclusion with FFAs

was associated with more pronounced soft tissue and dentoalveolar changes, including significant proclination and protrusion of mandibular incisors [16].

This is in accordance with our study and moreover, it was evident that FFA treatment has the highest risk of producing mandibular incisor proclination among all treatments under investigation.

5. CONCLUSION

Multibracket appliance (MBA) orthodontic treatment with Class II elastics alone is associated with the high risk of producing unfavorable mandibular incisor proclination, which takes place more rapidly when compared to the combination treatment of Class II elastics with the other appliances under investigation.

Removable appliance treatment in combination with MBA and Class II elastics reduces the risk and delays the occurrence of proclination,

- Fixed functional appliance treatment in combination with MBA and Class II elastics highly increases the risk of proclination.
- The use of the lingual arch in combination with MBA and Class II elastics retains the probability of risk at the early stages of treatment, however a high risk of incisor proclination occurs abruptly later in time.

REFERENCES

1. Broadbent BH. Ontogenic development of occlusion. *Angle Orthod.* 1941 Oct;11(4):223-241. [Google Scholar](#)
2. Margolis HI. The axial inclination of the mandibular incisors. *Am J Orthod Oral Surg.* 1943 Oct 1;29(10):571-594. [Google Scholar](#)
3. Tweed CH. The Frankfort-mandibular plane angle in orthodontic diagnosis, classification, treatment planning and prognosis. *Am J Orthod Oral Surg.* 1946 Apr;32:175-230. doi: 10.1016/0096-6347(46)90001-4. PMID: 21022281. [CrossRef PubMed Google Scholar](#)
4. Melsen B, Allais D. Factors of importance for the development of dehiscences during labial movement of mandibular incisors: a retrospective study of adult orthodontic patients. *Am J Orthod Dentofacial Orthop.* 2005 May;127(5):552-561; quiz 625. doi: 10.1016/j.jado.2003.12.026. PMID: 15877035.2005;127:552-561. [Full text links CrossRef PubMed Google Scholar Scopus WoS](#)
5. Gungor AY, Turkkahraman H, Yilmaz HH, Yariktas M. Cephalometric comparison of obstructive sleep apnea patients and healthy controls. *Eur J Dent.* 2013 Jan;7(1):48-54. PMID: 23408768; PMID: PMC3571509.2013;7:48-54. [Full text links CrossRef PubMed Google Scholar Scopus](#)
6. Faria PT, de Oliveira Ruellas AC, Matsumoto MA, et al. Dentofacial morphology of mouth breathing children. *Braz Dent J.* 2002;13(2):129-132. doi: 10.1590/s0103-64402002000200010. PMID: 12238804.2002;13:129-132. [CrossRef PubMed Google Scholar](#)
7. Proffit WR, Fields HW Jr, Moray LJ. Prevalence of malocclusion and orthodontic treatment need in the United States: estimates from the NHANES III survey. *Int J Adult Orthodon Orthognath Surg.* 1998;13(2):97-106. PMID: 9743642. [PubMed Google Scholar Scopus](#)
8. Janson G, Sathler R, Fernandes TMF, et al. Correction of Class II malocclusion with Class II elastics: a systematic review. *Am J Orthod Dentofacial Orthop.* 2013 Mar;143(3):383-392. doi: 10.1016/j.jado.2012.10.015. PMID: 23452973. [Full text links PubMed Google Scholar Scopus WoS](#)
9. Schulz KF, Altman DG, Moher D. Consort 2010 Statement: updated guidelines for reporting parallel group randomized trials. *Br Med Journal.* 2010;340:c332. doi:10.1136/bmj.c332. [Full text links PubMed Google Scholar Scopus](#)

6. ABBREVIATIONS

- CLII:** Class II elastics
RFA: Removable functional appliance
FFA: Fixed functional appliance
LA: Lingual arch
MBA: Multibracket appliance
HR: Hazard ratio
PSM: Propensity score matching
RCT: Randomized clinical trial
Tx: Treatment
ATE: Average treatment effect
SD: Standard deviation

CONFLICT OF INTEREST

None to declare.

FUNDING

This research did not receive any specific grant from funding agencies in the public, commercial, or not-for-profit sectors..

AUTHOR CONTRIBUTIONS

AT, MT: Data collection and interpretation, manuscript writing; **AC:** Conceptualization, methodology, manuscript writing, reviewing and editing; **MAP:** Conceptualization, methodology, supervision, reviewing and editing.

ACKNOWLEDGEMENTS

The authors acknowledge Mr. Evaggelos Akrivos for the statistical analysis of the data.

10. Austin PC, Laupacis A. A tutorial on methods to estimating clinically and policy-meaningful measures of treatment effects in prospective observational studies: a review. *Int J Biostat.* 2011;7(1):6. doi: 10.2202/1557-4679.1285. Epub 2011 Jan 6. PMID: 22848188; PMID: PMC3404554. [Full text links CrossRef PubMed Google Scholar Scopus WoS](#)
11. Laupacis A, Sackett DL, Roberts RS. An assessment of clinically useful measures of the consequences of treatment. *N Engl J Med.* 1988 Jun 30;318(26):1728-1733. doi: 10.1056/NEJM198806303182605. PMID: 3374545. [Full text links CrossRef PubMed Google Scholar Scopus WoS](#)
12. Cook RJ, Sackett DL. The number needed to treat: a clinically useful measure of treatment effect. *BMJ.* 1995 Feb 18;310(6977):452-454. doi: 10.1136/bmj.310.6977.452. Erratum in: *BMJ* 1995 Apr 22;310(6986):1056. PMID: 7873954; PMID: PMC2548824. [CrossRef Google Scholar Scopus WoS](#)
13. Jaeschke R, Guyatt G, Shannon H, et al. Basic statistics for clinicians: 3. Assessing the effects of treatment: measures of association. *Can Med Assoc J.* 1995 Feb 1;152(3):351-357. Erratum in: *Can Med Assoc J* 1995 Mar 15;152(6):813. PMID: 7828099; PMID: PMC1337533.357. [Full text links PubMed Google Scholar Scopus WoS](#)
14. Rosenbaum PR, Rubin DB. The central role of the propensity score in observational studies for causal effects. *Biometrika.* 1983 Apr 1;70(1):41-55. [Google Scholar Scopus WoS](#)
15. Schmoor C, Gall C, Stampf S, Graf E. Correction of confounding bias in non-randomized studies by appropriate weighting. *Biom J.* 2011 Mar;53(2):369-387. doi: 10.1002/bimj.201000154. Epub 2011 Feb 10. PMID: 21308726. [Full text links CrossRef PubMed Google Scholar Scopus WoS](#)
16. Zymperdikas VF, Koretsi V, Papageorgiou SN, Papadopoulos MA. Treatment effects of fixed functional appliances in patients with Class II malocclusion: a systematic review and meta-analysis. *Eur J Orthod.* 2016 Apr;38(2):113-126. doi: 10.1093/ejo/cjv034. Epub 2015 May 19. PMID: 25995359; PMID: PMC4914762. [Full text links CrossRef PubMed Google Scholar Scopus WoS](#)
17. Pangrazio-Kulbersh V, Berger JL, Chermak DS, et al. Treatment effects of the mandibular anterior repositioning appliance on patients with Class II malocclusion. *Am J Orthod Dentofacial*

Orthop. 2003 Mar;123(3):286-295. doi: 10.1067/mod.2003.8. PMID: 12637901.

[Full text links](#) [CrossRef](#) [PubMed](#) [Google Scholar](#) [Scopus](#) [WoS](#)

18. Panchez H, Bjerklind K. Mandibular incisor inclination, tooth irregularity, and gingival recessions after Herbst therapy: a 32-year follow-up study. *Am J Orthod Dentofacial Orthop.* 2014 Sep;146(3):310-318. doi: 10.1016/j.ajodo.2014.02.009. PMID: 25172253.

[Full text links](#) [CrossRef](#) [PubMed](#) [Google Scholar](#) [Scopus](#) [WoS](#)

19. Wein SL. The lingual arch as a source of anchorage in Class II treatment. *Am J Orthod.* 1959 Jan 1;45(1):32-49.

[Google Scholar](#)

20. Kanter F. Mandibular anchorage and extraoral force. *Am J Orthod.* 1956 Mar 1;42(3):194-208.

21. Proffit WR, Fields HW Jr. Contemporary orthodontics. 2nd edition. St. Louis: Mosby, 1993, p. 495-515.

[Google Scholar](#)

22. Graber TM. Combined extraoral and functional appliances. In: Graber TM (ed). *Dentofacial orthopedics with functional appliances.* 2nd edition. St. Louis: Mosby; 1997, p. 383-84.

[Google Scholar](#)

23. Meikle MC. The dentomaxillary complex and overjet correction in Class II, Division 1 malocclusion: objectives of skeletal and alveolar remodeling. *Am J Orthod.* 1980 Feb;77(2):184-197. doi: 10.1016/0002-9416(80)90006-8. PMID: 6928346.

[CrossRef](#) [PubMed](#) [Google Scholar](#) [Scopus](#)

24. Ellen EK, Schneider BJ, Sellke T. A comparative study of anchorage in bioprogressive versus standard edgewise treatment in Class II correction with intermaxillary elastic force. *Am J Orthod Dentofacial Orthop.* 1998 Oct;114(4):430-436. doi: 10.1016/s0889-5406(98)70189-1. PMID: 9790328.

[Full text links](#) [CrossRef](#) [PubMed](#) [Google Scholar](#) [Scopus](#) [WoS](#)

25. Dewey M. The use of the lingual arch in the treatment of malocclusion as used by Dr. Lloyd S. Lourie. *Int J Orthodontia.* 1916 Nov 1;2(11):648-661.

[Google Scholar](#)

26. Mershon JV. The removable lingual arch as an appliance for the treatment of malocclusion of the teeth. *Int J Orthodontia.* 1918 Nov 1;4(11):578-587.

[Google Scholar](#)

27. Chen CY, Hsu KC, Marghalani AA, et al. Systematic review and meta-analysis of passive lower lingual arch for resolving mandibular incisor crowding and effects on arch dimension. *Pediatr Dent.* 2019 Jan 15;41(1):9-22. PMID: 30803471.2019;41:9-19.

[Full text links](#) [PubMed](#) [Google Scholar](#) [Scopus](#) [WoS](#)

28. Viglianisi A. Effects of lingual arch used as space maintainer on mandibular arch dimension: a systematic review. *Am J Orthod Dentofacial Orthop.* 2010 Oct;138(4):382.e1-382.e4. doi: 10.1016/j.ajodo.2010.02.026. PMID: 20889031.

[Full text links](#) [CrossRef](#) [PubMed](#) [Google Scholar](#) [Scopus](#) [WoS](#)

29. Nelson B, Hansen K, Hägg U. Class II correction in patients treated with class II elastics and with fixed functional appliances: a comparative study. *Am J Orthod Dentofacial Orthop.* 2000 Aug;118(2):142-149. doi: 10.1067/mod.2000.104489. PMID: 10935954.

[Full text links](#) [CrossRef](#) [PubMed](#) [Google Scholar](#) [Scopus](#) [WoS](#)

30. Jayachandran S, Wiltshire WA, Hayasaki SM, Pinheiro FH. Comparison of AdvanSync and intermaxillary elastics in the correction of Class II malocclusions: a retrospective clinical study. *Am J Orthod Dentofacial Orthop.* 2016 Dec;150(6):979-988. doi: 10.1016/j.ajodo.2016.05.008. PMID: 27894547.

[Full text links](#) [CrossRef](#) [PubMed](#) [Google Scholar](#) [Scopus](#) [WoS](#)

31. Uzel A, Uzel I, Toroglu MS. Two different applications of Class II elastics with nonextraction segmental techniques. *Angle Orthod.* 2007 Jul;77(4):694-700. doi: 10.2319/071006-283. PMID: 17605495.

[Full text links](#) [CrossRef](#) [PubMed](#) [Google Scholar](#) [Scopus](#) [WoS](#)

32. Nelson B, Hägg U, Hansen K, Bendus M. A long-term follow-up study of Class II malocclusion correction after treatment with Class II elastics or fixed functional appliances. *Am J Orthod Dentofacial Orthop.* 2007 Oct;132(4):499-503. doi: 10.1016/j.ajodo.2005.10.027. PMID: 17920503.

[CrossRef](#) [Google Scholar](#) [Scopus](#)

Anastasia TSOLAKI

DDS, Postgraduate Student
 Health Professions Division
 Department of Orthodontics
 College of Dental Medicine
 Nova Southeastern University, FL, USA



CV

Anastasia Tsolaki, DDS, is a postgraduate student in Orthodontics at the Department of Orthodontics, College of Dental Medicine, Health Professions Division, Nova Southwestern University in Florida, USA since 2021. She received her Doctor of Dental Surgery degree from the Aristotle University of Thessaloniki, Greece in 2019. She has participated in a number of congresses and conferences in the dental and orthodontic field with poster or oral presentation. She has professional experience in dental and orthodontic practices since 2020. Her skills include knowledge of 3 foreign languages.

Questions

1. There is a higher risk of mandibular incisor proclination when:

- a. Fixed functional appliances are combined with multibracket appliance treatment;
- b. Removable appliances are combined with multibracket treatment and Class II elastics;
- c. Removable appliance alone are used;
- d. Lingual arch is used.

2. Which appliance retains the inclination of the lower incisors at the early stages of treatment?

- a. The multibracket appliance;
- b. The fixed functional appliance;
- c. The removable appliance;
- d. The lingual arch.

3. When does the risk of mandibular incisor proclination increase during treatment?

- a. At the early stages of multibracket appliance treatment;
- b. At the later stages of multibracket and Class II treatment, where lingual arch is used;
- c. At the early stages of treatment, where lingual arch is used;
- d. At the early stages of fixed functional treatment.

4. Which combination treatment delays the occurrence of lower incisor proclination?

- a. The combination of fixed functional appliance and multibracket appliance;
- b. The combination of Class II elastics with multibracket appliance;
- c. The combination of removable appliance, followed by multibracket appliance and Class II elastics;
- d. The combination of fixed functional appliance, multibracket appliance and Class II elastics.

ICCMO
The International College
of Cranio-Maxillofacial Orthopedics

ICCMO
The International College
of Cranio-Maxillofacial Orthopedics
INDIA SECTION

22nd Biennial
International Congress of
ICCMO
2023 GOA - INDIA

ನಮಾಫೀ ಇಕ್ಲಮ್
the airway truth

TMJ • OSA • CCMD • AIRWAY

4-7 May, 2023
The St. Regis Goa, India
register@iccmo2023india.com

<https://iccmo.org/home/event/india-2023>

ORAL REHABILITATION AND QUALITY OF LIFE IN PSYCHIATRIC PATIENTS UNDERGOING DEINSTITUTIONALIZATION

Ana María Morasso^{1-6a}, María Lujan Pérez Meyer^{1-5b}, Sergio Thefs^{1-4c}, Luciana D'Eramo^{2-3d}, Noemí Bordoni^{3e}, Aldo Fabián Squassi^{2-3f*}

¹Doctorado en Ciencias de la Administración, Facultad de Ciencias Económicas, Universidad Nacional de La Plata, Buenos Aires, Argentina

²Cátedra de Odontología Preventiva y Comunitaria, Facultad de Odontología, Universidad de Buenos Aires, Buenos Aires, Argentina

³Instituto de Investigaciones en Salud Pública, Facultad de Odontología, Universidad de Buenos Aires, Buenos Aires, Argentina

⁴Odontología Legal, Facultad de Odontología, Universidad Nacional de La Plata, Buenos Aires, Argentina

⁵Universidad Nacional de San Antonio de Areco, Buenos Aires, Argentina

⁶Especialización en Odontología Legal, Facultad de Medicina, Universidad del Salvador, Buenos Aires, Argentina

^aDDS; MS; PhD; Professor; e-mail: anamariamorasso@gmail.com; ORCIDiD: <https://orcid.org/0000-0001-7471-2383>

^bPhD; e-mail: malupm@gmail.com; ORCIDiD: <https://orcid.org/0000-0003-2251-4371>


^cPhD; e-mail: sergiothefs@gmail.com; ORCIDiD: <https://orcid.org/0000-0001-5378-2155>

^dDDS; Associated Professor; e-mail: luciana.deramo@odontologia.uba.ar; ORCIDiD: <https://orcid.org/0000-0003-0034-8835>

^eDDS; PhD; Emeritus Professor; e-mail: nbordoni14@gmail.com; ORCIDiD: <https://orcid.org/0000-0002-8147-9564>

^fDDS, PhD; Chairman, PhD; e-mail: aldo.squassi@odontologia.uba.ar; ORCIDiD: <https://orcid.org/0000-0001-7687-5805>

ABSTRACT

 [https://doi.org/10.25241/stomaedu.2022.9\(3-4\).art.4](https://doi.org/10.25241/stomaedu.2022.9(3-4).art.4)

Introduction Oral Health-Related Quality of Life (OHRQoL) measures can be used in mentally impaired groups to evaluate the consequences of oral health treatments. The objective of this study was to describe the impact of a prosthetic rehabilitation treatment on oral health-related quality of life in psychiatric adults in the process of deinstitutionalization.

Methodology We designed a quasi-experimental study to assess the OHRQoL of patients with mental disorders before and after prosthetic treatment on a sample of 165 institutionalized neuropsychiatric patients between 18 and 65 years of age ($x=50.24$ y.o.; $SD=7.85$). Before treatment, the validated Spanish version of OHIP-14 was filled out by each participant. Caries experience was assessed using the DMFT index. Sex, age, type of mental disorder, length of hospitalization, and permanence in a deinstitutionalization program were registered. The diagnoses of the psychiatric pathologies were transcribed from the medical records, following the DSM-IV criteria. The therapeutic intervention consisted in manufacturing and installing partial and complete removable acrylic prostheses, according to each patient's needs.

Results The sample had a DMFT index mean of 19.71 ($SD=5.54$). Missing teeth represented 86.86% of the total of the DMFT index. The OHIP-14 score before the intervention had a mean value of 26.06 ($SD=8.74$). After the prosthetic treatment, the OHIP-14 score had a mean value of 7.70 ($SD=3.96$). The statistical analysis revealed a significant difference between pre and post treatment intervention ($p=0.018$).

Conclusion This study showed that oral rehabilitation affected the oral health-related quality of life of patients with psychiatric disorders included in a social integration program.

KEYWORDS

Quality of Life; Deinstitutionalization; Mental Disorders; Oral Health; Prostheses and Implants

1. INTRODUCTION

People with mental disabilities frequently present poor oral health and require extensive dental treatment. Dental caries and periodontal disease are among the most common conditions affecting patients with psychiatric disorders [1]. Poor oral health can lead to pain, eating problems, sleeping disorders, and diminished self-esteem, all of which can affect an individual's quality of life. Oral health-related quality of life (OHRQoL) is a multidimensional

construct that has become a significant parameter to assess how oral health impacts daily function, well-being, and social interaction [1].

There is growing interest in quantifying the consequences of the disease that affect function, comfort, and the ability to carry out daily activities or the impact of health care services or the treatment of diseases. In general, dysfunction, discomfort, or disability measures can be used to assess the "burden of disease" or collectively the social impact [2].

 **OPEN ACCESS** This is an Open Access article under the CC BY-NC 4.0 license.

Peer-Reviewed Article

Citation: Morasso AM, Pérez Meyer ML, Thefs S, D'Eramo L, Bordoni N, Squassi AF. Oral rehabilitation and quality of life in psychiatric patients undergoing deinstitutionalization. *Stoma Edu J.* 2022;9(3-4):103-107.

Received: September 29, 2022; **Revised:** October 14, 2022 **Accepted:** October 21, 2022; **Published:** November 03, 2022.

***Corresponding author:** Prof. Aldo Fabián Squassi, Cátedra de Odontología Preventiva y Comunitaria, Facultad de Odontología, Universidad de Buenos Aires, MT de Alvear 2142, 5th floor, Suite B, CP 1122 Buenos Aires, Argentina, **Tel/Fax:** +54 11 5287 6253; e-mail: aldo.squassi@odontologia.uba.ar

Copyright: © 2022 the Editorial Council for the Stomatology Edu Journal.

Oral Health-Related Quality of Life (OHRQoL) measures are beginning to be used in mentally impaired groups with examinations and clinical trials and studies evaluating the consequences of oral health component programs. They also play an essential role in identifying needs, selecting therapies, and monitoring patient progress [3].

When OHRQoL measurements are used to accompany traditional clinical indicators to measure states of the oral health component, it is more understandable to assess the impact of the disease or the measures applied on some dimensions. These dimensions, which include functional limitation, physical pain, psychological discomfort, physical, psychological, social, and opportunity disability, do not exempt the analysis of other domains such as oral functions, orofacial pain, psychosocial impact, and appearance, which must also be described [4]. One of the proposed instruments is the Oral Health Impact Profile (OHIP) that assesses perceptions of the social impact of diseases or disorders and oral well-being. This questionnaire can be an excellent option to identify the dimensions of Oral Health-related to quality of life as it is a reliable instrument sensitive to changes and with adequate consistency in cultural crossing [5]. The objective of this study was to describe the impact of a prosthetic rehabilitation treatment on oral health-related quality of life in psychiatric adults in the process of deinstitutionalization.

2. METHODS AND MATERIALS

We designed a quasi-experimental study to assess the OHRQoL of patients with mental disorders before and after prosthetic treatment.

The target population was a universe of 240 neuropsychiatric patients from a monovalent institution of the Public Health System under the Outpatient and Assisted Rehabilitation Program for Social Integration. The study was carried out in the Community Mental Health Centers (CSMC) of La Plata (Province of Buenos Aires), institutions dependent on a regional hospital. A random sample of adults of both sexes was selected through systematic sampling, and institutional records were used for integration.

We included patients between 18 and 65 years old, with a permanence under the program for a period of more than two months. We excluded from the study patients who were already carriers of prosthetic rehabilitation in any of its types; patients with general motor function disorders classified as severe; and patients who, due to the characteristics, symptoms, and associated disorders of the psychiatric pathology, the medical criteria considered the use of prostheses as a risk.

In recognition of mental illnesses people's rights [6], the study was carried out with the authorization of the organization's executive staff and the consent of the authorities, curators, or legal representatives, as well as the consent of the patients.

Before treatment, the validated Spanish version of OHIP-14 [7] was filled out by each participant as a tool to measure OHRQoL. OHIP-14 includes 14 questions to assess how oral health influences psychosocial and physical domains of a person's life. A Likert scale was used for answering as below: 0-never, 1-hardly ever, 2-occasionally, 3-reasonably often, 4-very often. The total score of OHIP-14 is between 0 and 56, with higher scores indicating lower OHRQoL.

In addition, intraoral examinations to evaluate dental conditions were performed by a trained examiner. The examinations were conducted with the participant seated and the examiner using a head flashlight, a WHO dental probe, and a mirror. The data that describe the baseline situation of the oral health component obtained by direct observation were recorded in an individual file, with a graphic diagram of the dental state. This diagram representing the teeth allowed the registration based on predetermined symbols of all the prevalent pathology and the therapeutic resolution carried out before the moment of observation, with the precision of the tooth and each of the five surfaces that compose it. Caries experience was assessed using the decayed, missing, and filled teeth (DMFT index), based on the WHO criteria modified without taking into account code WHO1 (initial lesions without cavitation) due to difficulties in managing patients and ensuring appropriate dryness of dental surfaces. Caries experience was evaluated according to cavitated lesions ('D' component of the index).

Also, during the baseline examination, we registered the sex, age, type of mental disorder, length of hospitalization, and permanence in a deinstitutionalization program, and we considered independent variables. The diagnoses of the psychiatric pathologies were transcribed from the medical records, following the DSM-IV criteria [8]

The therapeutic intervention consisted of the manufacture and installation of partial and complete removable acrylic prostheses, according to the needs of each patient. The same operator carried out the treatment. Six months after the prosthetic treatment was completed, the patients were asked to fill out the OHIP-14 for the second time.

2.1 Statistical analysis

The observations were presented for the statistical treatment as ordinal scale enumeration data. The arithmetic, median, and dispersion mean, standard deviation and interquartile range were estimated as central tendency data.

Confidence intervals were calculated to infer the data results obtained from the sample to the target population. The distribution of the DMFT and OHIP14 values were analyzed using Box Plot, Q-Q Plot diagrams, and the Anderson-Darling, Cramer-Von Mises, Shapiro-France, and Kolmogorov-Smirnov numerical tests. The students' t and z-test for DMFT were used as hypothesis test. Mann Whitney's non-parametric test was used for OHIP14.

3. RESULTS

The sample was made up of 165 adults ($x = 50.24$ years old; $SD = 7.85$) of both sexes with a diagnosis of psychiatric pathologies in the process of deinstitutionalization, 97 females ($x = 51.91$ y.o.; $SD = 7.44$) and 68 males ($x = 48.97$ y.o.; $SD = 8.04$), without significant differences between gender ($p = 0.185$). The time of institutionalization prior to entering the deinstitutionalization program was 16.40 years (10.96), range 1-62 years. A significant positive correlation was determined between the age of the patients and the years of permanence in the hospitalization system prior to admission to the program ($r = 0.456$; $p < 0.05$). Regarding the average length of stay within the rehabilitation programs of the CSMC, it was 6.90 years (5.17), with no significant differences between both sexes ($p = 0.329$).

The DMFT index presented a mean (SD) of 19.71 (5.54) (Tab. 1).

Table 1. Distribution of DMFT index by sex.

	n	DMFT \bar{x} (SD)	D \bar{x}	M \bar{x}	F \bar{x}
Male	68	18.28 (5.36)	2.01	15.48	0,79
Female	97	21.59 (5.32)	1.23	19.27	1.09
Total	165	19.71 (5.54)	1.67	17.12	0.92

Missed teeth represented 86.86% of the total of the DMFT index. Significant differences were observed in the DMFT between genders ($p = 0.033$). When analyzing the DMFT values according to categories established according to DSM IV criteria, no significant differences were observed (Tab. 2).

Table 2. Distribution of DMFT index according psychiatric disorders.

	N	\bar{x}	SD
Schizophrenia	97	18,80	5,3
Mental retardation	39	21,41	5,24
Psychosis	13	21,50	8,06
Specific personality disorder	13	18,50	6,45
Substance addictions	3	24,00	0
Total	165	19,7	5,54

Regarding OHIP-14, the total score before the intervention has a median of 23, with a value of 20.50 for the first quartile and 26.50 for the third quartile, with an interquartile range of 3.5. The mean (SD) was 26.06 (8.74). After prosthetic treatment, OHIP-14 total score has a median of 6, with 5.00 for the first quartile and 10.00 for the third quartile, and an interquartile range of 4.00. The mean (SD) value was 7.70 (3.96). Statistical analysis reveals a significant difference between results pre and post treatment intervention ($p = 0.018$).

4. DISCUSSION

The proposal for the treatment of patients with chronic evolution pathologies in their reintegration into the community leads to the creation of devices that guide the therapeutic objectives to maintain clinical stability and include rehabilitation and social reintegration.

The study included combined clinical and subjective indicators for a multidimensional approach to the oral condition and the measurement of the impact of prosthetic rehabilitation on the quality of life as a driver of changes indicating an improvement in general health. This improvement will allow the inclusion in a comprehensive plan for the social reintegration of psychiatric adults. This study considers that the Health-Mental Illness categories are historically determined by macroeconomic and macrosocial factors with an evaluative charge of what is considered normal and pathological according to the context, the theoretical approaches and diagnostic criteria used, and the philosophical and moral conceptions, current psychological and prevailing medical models. Adults spend long periods in outpatient programs. This situation reveals that it can be questioned whether everything possible in terms of care units makes sense to be done. It is questioned whether the marginal return of the different activities is not very low as a function of the results due to diminishing returns in the face of biological limitations. The questions posed to dental care have resulted from factors that accompany the current model. Accumulated needs that require many clinical units can be highlighted, as well as long periods of hospitalization with an extension of treatments to reach discharge of patients. The oral component involves interventions for the care, prevention, and rehabilitation of prevalent diseases. There is growing interest in quantifying the consequences of oral diseases that affect function, comfort, and the ability to carry out daily activities, the burden of disease registered in different communities, or the social impact that they trigger [3].

In terms of dental conditions, the results of this study determined that oral health has not been a priority in government agendas for these special populations. Therefore, conventional dental care and oral rehabilitation had to face limitations and difficulties. In the province of Buenos Aires, the adults with mental disorders studied were going through an assisted externalization program for socio-labor reintegration with high levels of missed teeth. This situation affects the management of social skills and interpersonal relationships, which cannot be fully realized without rehabilitating the lost dental functionality.

Several studies found similar DMFT values in adults patients with psychiatric disorders [9,10,11,12,13,14], ranging from 16 to 25. This clinical variable allowed quantifying dental disease experience, determining a compromised oral health situation in our sample. The result of the measurement of functional and aesthetic capacities or the impact of the perceived

oral condition constituted an essential input in the individual evaluation of the residual consequence of the oral disease, such as tooth loss and the care provided [3]. While some outcomes related to prosthetic therapies are difficult to measure, satisfaction measurement can characterize such intervention benefits. These results are probably some of the most used as global indicators of the efficacy of prosthetic therapy in clinical practice or research [15]. John et al. studied the association between depression and dissatisfaction in older adults. Their results indicated that depression affects the perception of health and, in particular, perceived health, characterized by OHRQoL measurements. The authors found a significant association between depression and dissatisfaction with prosthetics in older adults, contributing to a wealth of data about the influence of depression on a variety of psychological and psychosocial outcomes in medical-dental treatments [16]. Several studies evaluated the effects of prosthetic rehabilitation on the quality of life and found an improvement after completing treatments [15,17]. With dementia patients, van de Rijt showed insufficient oral function, which was negatively associated with the quality of life and nutritional status [18].

REFERENCES

- Anders PL, Davis EL. Oral health of patients with intellectual disabilities: a systematic review. *Spec Care Dentist*. 2010 May-Jun;30(3):110-117. doi: 10.1111/j.1754-4505.2010.00136.x. PMID: 20500706.
[Full text links CrossRef PubMed Google Scholar Scopus](#)
- Vered Y, Soskolne V, Zini A, Livny A, Sgan-Cohen HD. Psychological distress and social support are determinants of changing oral health status among an immigrant population from Ethiopia. *Community Dent Oral Epidemiol*. 2011 Apr;39(2):145-153. doi: 10.1111/j.1600-0528.2010.00581.x. Epub 2010 Nov 11. PMID: 21070316.
[Full text links CrossRef PubMed Google Scholar Scopus WoS](#)
- Locker D, Jokovic A, Clarke M. Assessing the responsiveness of measures of oral health-related quality of life. *Community Dent Oral Epidemiol*. 2004 Feb;32(1):10-18. doi: 10.1111/j.1600-0528.2004.00114.x. PMID: 14961835.
[Google Scholar WoS](#)
- Lawrence HP, Thomson WM, Broadbent JM, Poulton R. Oral health-related quality of life in a birth cohort of 32-year olds. *Community Dent Oral Epidemiol*. 2008 Aug;36(4):305-316. doi: 10.1111/j.1600-0528.2007.00395.x. PMID: 18650957; PMCID: PMC2288569.
[Full text links CrossRef PubMed Google Scholar Scopus WoS](#)
- John MT, Hujoel P, Miglioretti DL, et al. Dimensions of oral-health-related quality of life. *J Dent Res*. 2004 Dec;83(12):956-960. doi: 10.1177/154405910408301213. PMID: 15557405.
[Google Scholar WoS](#)
- Republica Argentina. Ley de Salud Mental. Buenos Aires; 2010 p. *Boletin Oficial* 03/12/2010.
- Lopez R, Baelum V. Spanish version of the Oral Health Impact Profile (OHIP-Sp). *BMC Oral Health*. 2006 Jul 7;6:1-8. doi: 10.1186/1472-6831-6-11. PMID: 16827940; PMCID: PMC1534011.
[Full text links CrossRef PubMed Google Scholar](#)
- Diagnostic and statistical manual of mental disorders : DSM-IV [Internet]. Fourth edition. Washington, DC : *American Psychiatric Association*, [1994] ©1994; Available from: <https://search.library.wisc.edu/catalog/999733358502121>
- Denis F, Milleret G, Wallenhorst T, et al. Oral health in schizophrenia patients: a French multicenter cross-sectional study. *Presse Med*. 2019 Feb;48(2):e89-e99. doi: 10.1016/j.lpm.2018.06.018. Epub 2019 Mar 8. PMID: 30853291.
[Full text links CrossRef PubMed Google Scholar Scopus WoS](#)
- Jovanovic S, Milovanovic SD, Gajic I, et al. Oral health status of psychiatric in-patients in Serbia and implications for their

The aesthetic and functional rehabilitation of individuals is, in essence, the background of prosthodontics as a discipline. The impact of the change will be significantly different depending on how the person feels or perceives the deficit or that residual consequence, such as tooth loss.

5. CONCLUSION

This study showed that oral rehabilitation affected the oral health-related quality of life of patients with psychiatric disorders included in a social integration program.

AUTHOR CONTRIBUTIONS

AMM participated in the research objective proposal, research protocol design, clinical examinations and data collection procedures, and also in the scientific writing of the manuscript. **MLPM** participated in data interpretation and statistical analysis **ST** participated in the clinical examinations and data collection procedures. **LD** participated in data interpretation and the scientific writing of the manuscript. **NB** participated in the research protocol design and critical revision of the manuscript. **AS** participated in data interpretation and the scientific writing of the manuscript

- dental care. *Croat Med J*. 2010 Oct;51(5):443-450. doi: 10.3325/cmj.2010.51.443. PMID: 20960594; PMCID: PMC2969139.
[Full text links CrossRef PubMed Google Scholar Scopus WoS](#)
- Wey MC, Loh S, Doss JG, et al. The oral health of people with chronic schizophrenia: A neglected public health burden. *Aust N Z J Psychiatry*. 2016 Jul;50(7):685-694. doi: 10.1177/0004867415615947. *Epub* 2015 Nov 11. PMID: 26560842.
[Full text links CrossRef PubMed Google Scholar Scopus WoS](#)
 - Velasco-Ortega E, Monsalve-Guil L, Ortiz-Garcia I, et al. Dental caries status of patients with schizophrenia in Seville, Spain: a case-control study. *BMC Res Notes*. 2017 Jan 18;10(1):50. doi: 10.1186/s13104-016-2368-9. PMID: 28100262; PMCID: PMC5241932.
[Full text links CrossRef PubMed Google Scholar Scopus](#)
 - Ngo DYJ, Thomson WM, Subramaniam M, et al. The oral health of long-term psychiatric inpatients in Singapore. *Psychiatry Res*. 2018 Aug;266:206-211. doi: 10.1016/j.psychres.2018.05.048. Epub 2018 May 22. PMID: 29870958.
[Full text links CrossRef PubMed Google Scholar Scopus WoS](#)
 - Gurbuz O, Alatas G, Kurt E, Issever H, Dogan F. Oral health and treatment needs of institutionalized chronic psychiatric patients in Istanbul, Turkey. *Community Dent Health*. 2010 Sep;27(3):151-157. PMID: 21046906.
[Full text links PubMed Google Scholar Scopus WoS](#)
 - Strassburger C, Heydecke G, Kerschbaum T. Influence of prosthetic and implant therapy on satisfaction and quality of life: a systematic literature review. Part 1-Characteristics of the studies. *Int J Prosthodont*. 2004 Jan-Feb;17(1):83-93. PMID: 15008238.
[PubMed Google Scholar Scopus WoS](#)
 - John MT, Micheelis W, Steele JG. Depression as a risk factor for denture dissatisfaction. *J Dent Res*. 2007 Sep;86(9):852-856. doi: 10.1177/154405910708600909. PMID: 17720854.
[Full text links PubMed Google Scholar](#)
 - Hyde S, Satariano WA, Weintraub JA. Welfare dental intervention improves employment and quality of life. *J Dent Res*. 2006 Jan;85(1):79-84. doi: 10.1177/154405910608500114. PMID: 16373686; PMCID: PMC2248157.
[Full text links CrossRef PubMed Google Scholar Scopus WoS](#)
 - Van de Rijt LJM, Feast AR, Vickerstaff V, et al. Oral function and its association with nutrition and quality of life in nursing home residents with and without dementia: A cross-sectional study. *Gerodontology*. 2021 Dec;38(4):404-413. doi: 10.1111/ger.12535. Epub 2021 Jan 31. PMID: 33521997; PMCID: PMC9291735.
[Full text links CrossRef PubMed Google Scholar Scopus WoS](#)

Ana María MORASSO

Specialist in Legal Dentistry (Universidad del Salvador)
Master in Public Health (Universidad de Buenos Aires)
Master in Economics and Administration of Health Systems (Universidad Nacional de La Plata)
PhD in Administration Sciences (Universidad Nacional de La Plata)
Director of the Specialization Course in Legal Dentistry. (Universidad del Salvador)

**CV**

Professor Ana María Morasso is an educationist, researcher and specialist in legal and forensic dentistry from Argentina. She received her DDS from the School of Dentistry, Universidad Nacional de La Plata. She obtained a Speciality in Legal Dentistry degree at the Universidad del Salvador, a Master in Public Health degree at the Universidad de Buenos Aires and a Master in Economics and Administration of Health Systems at Universidad Nacional de La Plata. She finished her PhD in Administration Sciences at the Universidad Nacional de La Plata. At present, she has been appointed as Director of the Specialization Course in Legal Dentistry at the Universidad del Salvador in Buenos Aires, Argentina. She has participated in research projects accredited by different institutions and authored research papers published in national and international scientific journals.

Questions**1. Which is the role of Oral Health-Related Quality of Life measures in mentally impaired groups?**

- a. Identifying treatment needs, selecting therapies, and monitoring patient progress;
- b. Selecting patients to be treated with simplified techniques;
- c. Reducing costs of treatments;
- d. All of them are correct.

2. Which questionnaire was used in this study to measure Oral Health-Related Quality of Life?

- a. Oral Health Impact Profile (OHIP-14);
- b. Oral Health Impact Profile (OHIP-49);
- c. DMFT;
- d. Oral Health Assessment Tool (OHAT).

3. According DMFT index seen in this study, what is the need for oral rehabilitation in patients with mental disorders?

- a. No need;
- b. Low;
- c. Moderate;
- d. High.

4. What is the relationship between oral rehabilitation and the quality of life in patients with mental disorders?

- a. Impairs quality of life;
- b. Improves quality of life;
- c. Quality of life is not affected;
- d. There is no relation between oral health and quality of life.



Dentsply Sirona Imaging Solutions

Axeos. Experience the difference.

A new generation of progressive imaging is here – experience the difference with Axeos.

- 2D/3D hybrid device equipped with new technology and a broad Field of View (FoV) range, from a focused FoV (Ø5 x 5.5 cm) for endodontic cases up to a large FoV (Ø17 x 13 cm) that covers complete dentition, including both TMJs
- Seamless connectivity and individualized treatment workflow with Sidexis 4 Software
- Patient Positioning and Image Assistant (PIA) for increased patient comfort and image accuracy

Because every patient deserves a healthy, happy smile and every practice team deserves the tools to make this a reality. It's time to elevate and expand your treatment offer. It's time for Axeos.

For more information on Axeos please contact your local dealer,
Dentsply Sirona sales representative or visit

dentsplysirona.com/axeos

THE DENTAL
SOLUTIONS
COMPANY™

**Dentsply Sirona CEE Central
Office & Showroom**
Str. Vulturilor 98A, 030857, București
Tel.: 0774 074 094
office.romania@dentsplysirona.com
www.dentsplysirona.ro
<http://facebook.com/dentsplysirona.romania>

 **Dentsply
Sirona**

THE ORAL EFFECTS OF E-CIGARETTES – A LITERATURE REVIEW

Áron Imre Györkös^{1a}, Norbert Kulcsár^{2b}, Péter Hermann^{2c}, Barbara Kispélyi^{2d}

¹Szép és Ép Fog Kft., Budapest, Hungary

²Department of Prosthodontics, Faculty of Dentistry, Semmelweis University, Szentkirályi utca 47, HU-1088 Budapest, Hungary

^aPrivate Dentist; e-mail: aron.gyorkos@gmail.com; ORCID ID: <https://orcid.org/0000-0002-9657-6156>

^bDental Student; e-mail: kulcsar.norbert@stud.semmelweis.hu; ORCID ID: <https://orcid.org/0000-0003-3070-970X>

^cDMD, MSc, PhD, Professor and Head; e-mail: hermann.peter@dent.semmelweis-univ.hu; ORCID ID: <https://orcid.org/0000-0002-9148-0139>

^dDMD, PhD, Associate Professor; e-mail: kispelyi.barbara@dent.semmelweis-univ.hu; ORCID ID: <https://orcid.org/0000-0002-0530-0905>

ABSTRACT

 [https://doi.org/10.25241/stomaeduj.2022.9\(3-4\).art.5](https://doi.org/10.25241/stomaeduj.2022.9(3-4).art.5)

Background Because of regulations made against smoking, and the rising popularity of a healthy lifestyle there has been a visible change in the smoking habit of the population in the last 15 years. The negative impact on the attitude toward smoking forced the industry to develop new ways to satisfy the consumer's nicotine need. That is how heated tobacco products and a variety of ENDS (Electronic Nicotine Delivery System), such as electronic cigarettes) have been invented.

Objective This literature review aims to summarise the oral effects of consuming e-cigarettes which have been proven and publicised.

Data Sources The main source of the study has been the publications found through PubMed and NCI (National Center for Biotechnology Information).

Study Selection Articles have been selected from the international literature if they had any information on the oral effects of e-cigarettes.

Data Extraction The information from the articles has been categorised based on the tissue and the time they last.

Data Synthesis Electronic cigarettes cause a change in saliva flow and its composition, a decrease in the blood supply of soft tissues and an immunosuppressed state in the said area, therefore the incidence of some diseases are higher among the users. Components of the e-liquid may cause damage to both soft and hard tissues, such as cancerous lesions, inflammation, chronic periodontitis and neurodegeneration. Nicotine may be absorbed by the surface of the teeth, causing patches, and some ingredients may be beneficial to the bacterial flora of the oral cavity.

KEYWORDS

E-Cigarette; Electronic Nicotine Delivery Systems; Oral Health; Nicotine; Smoking

1. INTRODUCTION

Over the last few years, electronic cigarettes (e-cigarettes) have gained greater and greater popularity. According to a 2011 survey by the WHO (World Health Organisation), 7 million people used e-cigarettes regularly worldwide at the time, and this number increased to 41 million by 2018 [1]. Some forecasts indicate that the popularity of e-cigarettes will not change; furthermore, as of 2021, there are an estimated 55 million daily users [1]. Concerning the health effects of e-cigarettes, they are thought to be a healthy alternative to smoking, a notion rooted in the marketing strategy and other factors of the tobacco industry. Another problem is that these products are accessible to a younger demographic: in 2020 alone in the USA, 19.6% of surveyed secondary school students used e-cigarettes, and 22.5% used them as a daily routine [2]. The harmful effects of traditional cigarettes are already established knowledge in people's awareness, thanks to widespread effort to combat the habit of

smoking in the population; however, when it comes to e-cigarettes, no similar action has been underway, allowing their popularity to increase on and on. Over the last years worldwide, countless research studies have aimed to describe the health effects of electronic cigarettes, which indicates that there are many questions without answers. For this reason, this article aims to summarize present knowledge concerning the oral effects of using electronic cigarettes.

2. CHANGES IN THE SALIVA FLOW AND ITS CONSEQUENCES

Traditional cigarettes burn at almost 1000 degrees Celsius and produce quite toxic by-products at this high temperature, for instance, tar. In contrast, during the use of electronic cigarettes, there is no burning; instead, they vaporize liquid content at a much lower temperature, so the exhaled vapour is assumed to contain fewer toxic components [3]. The temperature of the vapour emitted by the e-cigarette depends on

 **OPEN ACCESS** This is an Open Access article under the CC BY-NC 4.0 license.

Peer-Reviewed Article

Citation: Györkös ÁI, Kulcsár N, Hermann P, Kispélyi B. The oral effects of e-cigarettes – a literature review. *Stoma Edu J.* 2022;9(3-4):109-114.

Received: July 19, 2022; **Revised:** September 29, 2022; **Accepted:** October 21, 2022; **Published:** November 03, 2022.

***Corresponding author:** Norbert Kulcsar, Faculty of Dentistry, Semmelweis University, Szentkirályi utca 47, HU-1088 Budapest, Hungary

Tel: +36 70633 3583; **Fax:** +36 1317 5270; e-mail: kulcsar.norbert@stud.semmelweis.hu

Copyright: © 2022 the Editorial Council for the Stomatology Edu Journal.

several factors such as battery voltage, resistance, atomiser condition, mouthpiece size, and e-liquid composition (mainly the level of propylene glycol (PG) and glycerine content); furthermore, some devices have adjustable voltage, so the temperature can vary quite widely. Generally, it can be stated that the average temperature of vaporizing is about 157 to 266 degrees Celsius [3]. The result of the extremely high-temperature vapour (mainly of PG-based liquids) may be the formation of substances containing a carbonyl group such as formaldehyde or acetaldehyde, which cause inflammation in the oral mucosa [4,5]. The most common and important condition that the vapour-induced temperature increase causes is xerostomia. The change in the saliva flow is assessed by measuring the resting and stimulated saliva flow. Symptoms of xerostomia may be a sticky or burning sensation in the oral cavity, increased thirst, difficulties in talking, swallowing, and tasting, and halitosis. Furthermore, the dried-out mucosa has a greater risk to develop oral infections such as oral candidiasis, which can recur from time to time. Besides these, the user's oral hygiene deteriorates [6], and the saliva's washing effect is compromised, therefore the incidence of caries rises [7]. Using an electronic cigarette changes not just the quantity of saliva but the quality as well. Oral pH is driven into the acidic range by nicotine; however, nicotine-free liquids move oral pH into the basic range and the saliva's buffer capacity is not affected [8]. Changes to the saliva's composition are also notable: the amount of secretory IgA, lysozyme, and lactoferrin is different from the physiologic level. Secretory IgA is a specialized antibody for the oral cavity containing saliva. The lysozyme content of saliva is detrimental to the immune processes: because of its proteolytic function, it breaks down antibodies. B-lymphocytes that have met antibodies migrate to one of the salivary glands and transform into plasma cells. In addition to monomer IgA, these cells produce a protein called J-protein, which connects IgA molecules by their Fc regions to form a dimer; this way, the lysozyme recognising the Fc regions becomes ineffective against these IgA dimers [9]. After the use of an electronic cigarette, it is proved by ELISA testing that the amount of IgA is decreased, which leads to a weakened oral immune response [10]. Lysozyme is responsible for breaking the bond between N-Acetylglucosamine and N-Acetylmuramic acid; these being the components of the bacterial cell walls, the action causes the lysis of bacteria. The substance also has antiviral and antifungal functions. As an effect of using e-cigarettes, the amount of lysozyme decreases, causing a downturn in oral protection [10]. Lactoferrin is an iron-binding glycoprotein, a multifunctional molecule participating in numerous physiological processes. Concerning the oral cavity, it is produced by the serous cells of the salivary glands; like lysozyme, it has antibacterial, antiviral, and antifungal effects, and is also an important immunomodulator. As an effect of using e-cigarettes, its level increases;

the extra quantity may be considered an indicator of oral inflammation [10].

3. CHANGES CAUSED BY VACUUM

During the use of an electronic cigarette, there is suction in the oral cavity, the size of which depends on the type of equipment, and its duration on the user's habits. The suction power is produced by the mimic muscles, and its consequence is a relative vacuum in the oral cavity. In a University of California 2010 study, the researchers ran tests on the most popular e-cigarettes of that time, assessing the level of effort needed to use an e-cigarette and the health effects of the arising vacuum. They measured the pressure by a manometer attached to a machine mimicking smoking and found that the user needed to generate greater suction power with any type of e-cigarette than with traditional ones. In the first ten suction cycles, the density of the vapour did not change; after the tenth suction cycle, however, it started to decrease continuously. The longer the e-cigarette had been used the greater effort was needed for the same amount of vapour. The generated vacuum, the density of the vapour and the required effort varied across device types [11]. There is no unified medical position yet on the health effects caused by the vacuum; further studies are needed, but the presumed consequences are the overload of the tongue and mimic muscles. The result of the greater suction power is that the vapour travels to the distal parts of the lung, reaching deeper regions, with all associated disadvantageous consequences [12].

4. EFFECTS ON DIFFERENT ORAL TISSUES

4.1 Soft Tissues: Acute Changes

As an effect of e-cigarette vapour, the blood supply of the soft tissues decreases, which can be traced back to two reasons. On the one hand, the chronic nicotine supply has a vasoconstrictor effect; on the other, the use of nicotine-free e-cigarettes decreases the blood supply as well. This is explained by glycerine and propylene-glycol inducing endothelial inflammation, which decreases the ability of veins to dilate so they stay constricted [13]. A decrease in blood flow can have numerous consequences such as decreased tissue defence and a hypoxic milieu, which can cause changes in the bacterial microbiome, leading to the proliferation of anaerobic species. Periodontal index values become higher, and the tendency to regenerate decreases, which leads to slow or failed wound healing [8].

Propionaldehyde, which appears in the aerosol during the decomposition of propylene-glycol, leads to the irritation of the oral cavity and the throat, with sensitivity, redness, and dry cough [14]. The symptoms of irritation tend to alleviate with continued use. Nicotine can cause a burning sensation by the activation of the TRPA1 (transient receptor potential ankyrin) channel [15].

As a result of the immunosuppressed state in the oral cavity, the incidence of infectious mucosal diseases, mainly candidiasis caused by *Candida albicans*, increases among e-cigarette users. It has been proved by in vitro experiments that in candida cells exposed to e-cigarette vapour, the expression of chitin and SAP-2,3,9 (secreted aspartic protease) increases, and a change takes place in the phenotype: the hyphae become longer. These changes help the adhesion of candida to the oral mucosa [16].

Upon exposure to some components of the vapour such as carbonyls, reactive oxygen radicals, and different types of aldehydes, the cytokine secretion of epithelial cells increases, which causes inflammation [17]. The components of e-liquid may cause an allergic reaction depending on one's immune system.

The prevalence of some mucosal diseases is higher among e-cigarette users. One such disease is stomatitis nicotina palati; induced by nicotine, the lesion mainly occurs on the hard palate, appearing as hyperkeratotic patches. Another disease occurring more often is lingua villosa nigra (black hairy tongue), causing the enlargement of the tongue's papillae and a change in colour to black. The risk of the disease cheilitis angularis also increases; this is a state associated with the bilateral drying and cracking of the anguli oris, which can be superinfected by some candida species [18].

4.2 Soft Tissues: Chronic Changes

Several components of e-liquids may damage the epithelial cells, which can cause the death of these cells, leading to ulcerative areas and wounds. During the use of an e-cigarette, metal particles may get into the aerosol from the atomiser or the cotton wool, including cadmium, nickel, and arsenic. Metal particles cause cancerous lesions, inflammation, chronic periodontitis, and neurodegeneration. As a result of heat and atomizing, flavouring substances decompose to carbonyls such as diacetyl. The main ingredients (propylene glycol and glycerine) decompose because of the heat, and among the decomposition products there are molecules containing a carbonyl group (formaldehyde, acetaldehyde) and reactive oxygen species (ROS). These molecules are cytotoxic regardless of the nicotine content; they induce DNA damage in the oral epithelium. They decrease the cells' defence via antioxidants, which would protect the cell against the reactive radicals; apoptosis and inflammation are induced. Carbonyl compounds cause protein carbonylation and oxidative stress. The consequence of all the above is a decrease in proliferative capacity and viability [15].

The volatile organic compounds with the potential for carcinogenicity in the e-cigarettes' vapour have a genotoxic effect [19]. Compared to traditional cigarettes, e-cigarettes have fewer carcinogenic substances at lower levels, but further studies are needed to find out if e-cigarettes can cause malignant transformations. The difficulties to judge the situation

include the lack of long-term experiments and participant recruitment challenges since the ideal subject would be a person who has never smoked and does not have any risk factors. Despite the shortage of clinical proof, current medical opinion states that because there are carcinogenic components and adverse changes induced in cells, using an e-cigarette could have a carcinogenic effect [20].

4.3 Hard Tissues: Teeth

Nicotine can be absorbed by the surface of the teeth, causing yellowish-brown patches [21]. During the degradation of propylene-glycol, which is one of the components of the e-liquid, acidic substances such as acetic acid or lactic acid are produced, which can directly damage the enamel [22]. Furthermore, propylene-glycol is a quite hygroscopic substance: it binds the water from saliva and soft tissues, further increasing the rate of xerostomia already developed, along with all the adverse consequences [22]. During a 2018 research, enamel was incubated in flavoured and non-flavoured e-cigarette vapour; measuring their hardness, the researchers found that the enamel treated with flavoured vapour was 27% softer than the other preparation. Considering these results, flavours may promote the demineralisation of enamel. The pathomechanism of this process is that triacetin (traditional tobacco flavour), hexyl acetate (apple flavour), and ethyl butyrate (pineapple flavour) are all esters, sources of nutrients for cariogenic bacteria, mainly for *Streptococcus mutans*. They facilitate the extracellular polymer formation of bacteria, which is the main process of biofilm generation, and they promote bacterial growth. During the degradation of carbohydrates, acids are generated, mainly lactic acid, decreasing pH and causing the demineralisation of teeth [23].

The metal content of e-cigarette vapour is beneficial for the bacteria as well because it contains iron, copper, and magnesium ions, which are the cofactors of some of the essential enzymes in *Streptococcus mutans*, and help the bacteria survive the attacks of the immune system. Researchers think e-liquid flavours are like fizzy drinks considering all things above, because of their cariogenic potency [23]. E-liquids usually contain glycerine as well, which is a desiccant like propylene-glycol. In the food industry, it is used as a sweetener, but cariogenic bacteria cannot break it down, meaning it does not facilitate the development of caries this way. On the other hand, through its viscosity, it helps bacterial adhesion to the surface of teeth; with the flavours in the e-liquid, it quadruples microbial adhesion to enamel, and the bacterial biofilm's size becomes twice as large [23]. The result of dental tissue weakening may be the fracture of enamel or fracture of an entire tooth. During a 2016 cross-sectional study, 11.4% of young respondents reported such damage to their teeth, proving the scientific position that with the use of e-cigarettes, the number of cracks and fractures of teeth increases [24].

4.4 Hard Tissues: Bone

Some ingredients of e-liquids are harmful to bone cells, affecting the cells' viability, differentiation, proliferative capacity, and matrix production. Cadmium found in e-liquid causes a decrease in the lifetime of osteoblasts even at a small concentration; furthermore, it increases the risk of certain musculoskeletal diseases such as rheumatoid arthritis and osteoarthritis [25,26].

In a 2019 experiment series, the effect of different flavouring substances of e-liquids on bone cells was assessed: osteoblasts were exposed to the most popular flavoured e-liquids, both nicotine-containing and nicotine-free, for 48 hours, then the cells' viability and their main osteoblast markers were evaluated. Results showed an increase in the expression of type I collagen, and the conclusion was that e-cigarettes are osteotoxic: all e-liquids decreased the viability of the cells, which was explained by oxidative stress and a higher level of reactive oxygen radicals. The rate of osteotoxicity was determined by the dosage and the flavour but was unrelated to nicotine content. Considering these findings, flavourless e-liquid is the least harmful, and cinnamon flavoured is the most cytotoxic [25].

The negative effects of e-cigarettes cause a change in the bone's features, and a decrease in its density and mineral content, which is dangerous mainly in childhood because this period is crucial in proper bone growth and development, this being the time when 90% of the bone mass develops. A long-time consequence of the change in the bones' condition might be osteoporosis [25], thus bone fractures might occur more frequently; furthermore, as an effect of nicotine, the regeneration of bone fractures is disturbed as well [27]. The changes in the bone's condition start in about two months of e-cigarette use; upon quitting, the alveolar bone recovers to its original, healthy state [28].

4.5 Effects on the Periodontium

The duty of the periodontium is anchoring, and fixing the teeth in the tooth ridge. The inflammation of periodontal tissues may lead to losing all the teeth, meaning that a healthy periodontium is necessary to keep and maintain one's teeth. Traditional cigarettes are well known for leading to periodontitis; the question here is if e-cigarettes have this consequence, too. Because of the vasoconstrictor effect of nicotine, the gingiva's oxygen and nutrition supply decrease. The consequence is a decrease in local white blood cell count, followed by these cells' inability to fulfil their defensive role, reinforced by low levels of lysozyme as a result of reduced saliva flow. On the other hand, there are consequential changes to the microbiome of the oral cavity, creating perfect circumstances for anaerobic periodonto-pathogenic bacteria to multiply, such as *Porphyromonas gingivalis*, *Aggregatibacter actinomycetemcomitans* and *Prevotella intermedia*. As a result of weakened defence and bacterial colonisation, inflammation,

gingivitis, and periodontitis may develop [4]. The symptoms of such gingivitis include pain, redness and bleeding-while-brushing of the gingiva [17].

It is quite interesting that according to research on the microbiome of the saliva, done on 119 participants, some gram-negative bacteria such as periodonto-pathogenic *Porphyromonas* and *Veillonella* occur in a greater quantity in e-cigarette users' saliva than in that of traditional smokers, showing e-cigarettes' potential harm leading to periodontitis [29].

Furthermore, nicotine is antiproliferative to fibroblasts: as a result of prostaglandins and matrix metalloproteases released upon exposure to nicotine, myofibroblast and mesenchymal stem cell differentiation are blocked, holding back wound healing. Osteoblast functions and new vessel growth are similarly suppressed, negatively impacting the success rate of implant dentures, osteointegration, and the regeneration of papillae. Decreased osseointegration has been confirmed by animal experiments: around implants in rats getting a nicotine injection, the size of BIC (Bone Implant Contact), i.e., the contact surface between bones and implants, was lower than in the control group [27].

The components of the periodontium – gingival fibroblasts, periodontal ligaments, and epithelial cells – develop and maintain inflammation as a response to specific stimuli or stress caused mainly by cytokines. Some components of the vapour of e-cigarettes such as reactive oxygen substances, aldehydes and compounds containing a carbonyl group, are among the triggers of inflammation. The potential inflammatory effects of carbonyl compounds include carbonylation of proteins, leading to autoantibody production and periodontal destruction [30]. Furthermore, the stress caused by these compounds gives rise to DNA damage, which translates to early cell ageing. In vitro experiments have proved that gingival fibroblasts exposed to e-cigarette vapour face a greater risk of necrosis and apoptosis [30].

Periodontitis is a multifactorial disease where the presence of bacteria is a necessary but not sufficient condition; the effects of e-cigarette vapour provide a favourable medium for the development of this disease. The depth of an e-cigarette user's periodontal sac increases, the developed gingivitis may cause sensitivity and bleeding, and the plaque index increases.[17] The risk of periodontitis increases, which leads to tissue and bone destruction, tooth mobility and, in the worst case, tooth loss.

5. CONCLUSION

The main purpose of inventing e-cigarettes was to find a less harmful alternative to traditional cigarettes; it is therefore useful to compare the health effects of these two harmful habits. In numerous cases, the e-cigarettes' harmful effects on the oral cavity are milder than those of traditional cigarettes; however, they have several adverse effects and may cause

severe diseases. A further danger of e-cigarettes is that there are various types of devices and e-liquids, making the uniformity of regulations and medical research more difficult. Even though much research has been done in this area, there are still numerous unanswered questions and statements awaiting proof. Despite our lack of knowledge, the opinion

on e-cigarettes' health effects are clear: they may be a useful assistive device while quitting traditional cigarettes, but they are unadvised to use in other cases due to their negative effects on oral tissues.

AUTHOR CONTRIBUTIONS

All authors agree to be accountable for the content of the work.

REFERENCES

- Jones L. Vaping: how popular are e-cigarettes. *BBC News*. 2019 Sep;14. Available from: <https://www.bbc.com/news/business-44295336>, Sep. 13, 2019. [Fulltextlinks](#)
- Wang TW, Neff LJ, Park-Lee E, et al. E-cigarette use among middle and high school students - United States, 2020. *MMWR Morb Mortal Wkly Rep*. 2020 Sep 18;69(37):1310-1312. doi: 10.15585/mmwr.mm6937e1. PMID: 32941408; PMCID: PMC7498174. [CrossRef Free PMC Article PubMed Google Scholar](#)
- Li Y, Burns AE, Tran LN, et al. Impact of e-liquid composition, coil temperature, and puff topography on the aerosol chemistry of electronic cigarettes. *Chem Res Toxicol*. 2021 Jun 21;34(6):1640-1654. doi: 10.1021/acs.chemrestox.1c00070. Epub 2021 May 5. PMID: 33949191. [CrossRef PubMed Google Scholar Scopus](#)
- Rajhans N, Sabale D, Patil T, et al. Can vaping affect the periodontal health? A review. *Int. J. of Sci. and Res*. vol. 2018 Nov. 7(11):1491-1492. [Full text link](#)
- Zhou Y, Irshad H, Dye WW, et al. Voltage and e-liquid composition affect nicotine deposition within the oral cavity and carbonyl formation. *Tob Control*. 2021 Sep;30(5):485-491. doi: 10.1136/tobaccocontrol-2020-055619. Epub 2020 Jun 25. PMID: 32587113. [CrossRef PubMed Google Scholar Scopus](#)
- Kaán R, Péntzes M, Abafalvi L, et al. Oral hygiene practices of hungarian adult E-cigarette-only and dual users. *Oral Health Prev Dent*. 2020 Nov 20;18(11):991-998. doi: 10.3290/j.ohpd.a45520. PMID: 33215490. [CrossRef PubMed Google Scholar Scopus](#)
- A seemingly harmless disease, The clinic and treatment options for xerostomia, *MOSZ Info*, Mar. 2017. [Full text link](#)
- Jones SL, Jones PK, Katz J. A nursing intervention to increase compliance in otitis media patients. *Appl Nurs Res*. 1989 May;2(2):68-73. doi: 10.1016/s0897-1897(89)80048-5. PMID: 2719485. [CrossRef PubMed Google Scholar Scopus](#)
- Bakema JE, van Egmond M. Immunoglobulin A: A next generation of therapeutic antibodies? *MAbs*. 2011 Jul-Aug;3(4):352-361. doi: 10.4161/mabs.3.4.16092. Epub 2011 Jul 1. PMID: 21691145; PMCID: PMC3218532. [CrossRef Free PMC Article PubMed Google Scholar](#)
- Cichońska D, Kusiak A, Kocharńska B, et al. Influence of electronic cigarettes on selected antibacterial properties of saliva. *Int J Environ Res Public Health*. 2019 Nov 12;16(22):4433. doi: 10.3390/ijerph16224433. PMID: 31726698; PMCID: PMC6888580. [CrossRef Free PMC Article PubMed Google Scholar Scopus](#)
- Trtchounian A, Williams M, Talbot P. Conventional and electronic cigarettes (e-cigarettes) have different smoking characteristics. *Nicotine Tob Res*. 2010 Sep;12(9):905-912. doi: 10.1093/ntr/ntq114. Epub 2010 Jul 19. PMID: 20644205. [CrossRef PubMed Google Scholar](#)
- Science Daily. Electronic cigarettes require more suction than conventional brands. *Science News*. University of California - Riverside, Jul. 2010. Available from: <https://www.sciencedaily.com/releases/2010/07/100728144349.htm> [Full text link](#)
- Caporale A, Langham MC, Guo W, et al. Acute effects of electronic cigarette aerosol inhalation on vascular function detected at quantitative MRI. *Radiology*. 2019 Oct;293(1):97-106. doi: 10.1148/radiol.2019190562. Epub 2019 Aug 20. PMID: 31429679; PMCID: PMC6776371. [CrossRef Free PMC Article PubMed Google Scholar Scopus](#)
- Callahan-Lyon P. Electronic cigarettes: human health effects. *Tob Control*. 2014 May;23 Suppl 2(Suppl 2):ii36-40. doi: 10.1136/tobaccocontrol-2013-051470. PMID: 24732161; PMCID: PMC3995250. [CrossRef Free PMC Article PubMed Google Scholar](#)
- Ebersole J, Samburova V, Son Y, et al. Harmful chemicals emitted from electronic cigarettes and potential deleterious effects in the oral cavity. *Tob Induc Dis*. 2020 May 8;18:41. doi: 10.18332/tid/116988. PMID: 32435175; PMCID: PMC7233525. [CrossRef Free PMC Article PubMed Google Scholar Scopus](#)
- Alanazi H, Semlali A, Chmielewski W, Rouabhia M. E-cigarettes increase *Candida albicans* growth and modulate its interaction with gingival epithelial cells. *Int J Environ Res Public Health*. 2019 Jan 21;16(2):294. doi: 10.3390/ijerph16020294. PMID: 30669681; PMCID: PMC6352080. [CrossRef Free PMC Article PubMed Google Scholar Scopus](#)
- Rouabhia M. Impact of electronic cigarettes on oral health: a review. *J Can Dent Assoc*. 2020 Mar;86:k7. PMID: 32543367. [Full text links PubMed Google Scholar Scopus](#)
- Bardellini E, Amadori F, Conti G, Majorana A. Oral mucosal lesions in electronic cigarettes consumers versus former smokers. *Acta Odontol Scand*. 2018 Apr;76(3):226-228. doi: 10.1080/00016357.2017.1406613. Epub 2017 Nov 21. PMID: 29161938. [CrossRef PubMed Google Scholar Scopus](#)
- Ganapathy V, Manyanga J, Brame L, et al. Electronic cigarette aerosols suppress cellular antioxidant defenses and induce significant oxidative DNA damage. *PLoS One*. 2017 May 18;12(5):e0177780. doi: 10.1371/journal.pone.0177780. PMID: 28542301; PMCID: PMC5436899. [CrossRef Free PMC Article PubMed Google Scholar Scopus](#)
- Raj AT, Sujatha G, Muruganandhan J, et al. Reviewing the oral carcinogenic potential of E-cigarettes using the Bradford Hill criteria of causation. *Transl Cancer Res*. 2020 Apr;9(4):3142-3152. doi: 10.21037/tcr.2020.01.23. PMID: 35117678; PMCID: PMC8798817. [CrossRef Free PMC Article PubMed Google Scholar Scopus](#)
- "Is Vaping Bad for Your Teeth? 7 Things to Know About Its Effects on Your Oral Health," Available from: <https://www.healthline.com/health/dental-and-oral-health/dental-and-oral-health-is-vaping-bad-for-your-teeth>. [Full text links](#)
- Froum S, Neymark A. Vaping and oral health: It's worse than you think. *Perio-Implant Advisory*. 2019 May. Available from: <https://www.perioimplantadvisory.com/clinical-tips/article/16412201/vaping-and-oral-health-its-worse-than-you-think-Jan-10-2019>. [Full text links](#)
- Kim SA, Smith S, Beauchamp C, et al. Cariogenic potential of sweet flavors in electronic-cigarette liquids. *PLoS One*. 2018 Sep 7;13(9):e0203717. doi: 10.1371/journal.pone.0203717. PMID: 30192874; PMCID: PMC6128655. [CrossRef Free PMC Article PubMed Google Scholar Scopus](#)
- Cho JH. The association between electronic-cigarette use and self-reported oral symptoms including cracked or broken teeth and tongue and/or inside-cheek pain among adolescents: a cross-sectional study. *PLoS One*. 2017 Jul 11;12(7):e0180506. doi: 10.1371/journal.pone.0180506. PMID: 28700729; PMCID: PMC5507461. [CrossRef Free PMC Article PubMed Google Scholar](#)
- Fiani B, Noblett C, Nanney JM, et al. The impact of 'vaping' electronic cigarettes on spine health. *Cureus*. 2020 Jun 29;12(6):e8907. doi: 10.7759/cureus.8907. PMID: 32742873; PMCID: PMC7389958. [CrossRef Free PMC Article PubMed Google Scholar](#)

26. Reyes-Hinojosa D, Lozada-Pérez CA, Zamudio Cuevas Y, et al. Toxicity of cadmium in musculoskeletal diseases. *Environ Toxicol Pharmacol.* 2019 Nov;72:103219. doi: 10.1016/j.etap.2019.103219. Epub 2019 Aug 15. PMID: 31494513. [CrossRef PubMed Google Scholar Scopus](#)

27. Kazi S, Khader AA, Sheth AM, et al. Effects of vaping on periodontium - a review. *J of Adv. Med. and Dental Sci. Res.* 2020 Feb 1;8(2):69-72. [Full text links Google Scholar](#)

28. César-Neto JB, Benatti BB, Sallum EA, et al. The influence of cigarette smoke inhalation and its cessation on the tooth-supporting alveolar bone: a histometric study in rats. *J Periodontal Res.* 2006 Apr;41(2):118-123. doi: 10.1111/j.1600-0765.2005.00844.x. PMID: 16499714. [CrossRef PubMed Google Scholar Scopus](#)

29. Pushalkar S, Paul B, Li Q, et al. Electronic cigarette aerosol modulates the oral microbiome and increases risk of infection. *iScience,* 2020 Mar 27;23(3):100884. doi: 10.1016/j.isci.2020.100884. Epub 2020 Feb 26. PMID: 32105635; PMCID: PMC7113564. [CrossRef Free PMC Article PubMed Google Scholar Scopus](#)

30. Javed F, Kellesarian SV, Sundar IK, Romanos GE, Rahman I. Recent updates on electronic cigarette aerosol and inhaled nicotine effects on periodontal and pulmonary tissues. *Oral Dis.* 2017 Nov;23(8):1052-1057. doi: 10.1111/odi.12652. Epub 2017 Mar 30. PMID: 28168771; PMCID: PMC5545167. [CrossRef Free PMC Article PubMed Google Scholar Scopus](#)

Áron Imre GYÖRKÖS

DMD, Clinical Doctor
 Szép és Ép fog Kft.
 Érd, Hungary



CV

Dr. Áron Imre Györkös, DMD, graduated from the Faculty of Dentistry, Semmelweis University, Budapest, Hungary in 2021. He is currently working as a dentist in Érd, next to Budapest, both in the public and private sector. The title of his research is The oral effects of e-cigarettes - a literature review. He started exploring this topic as his thesis and tried to summarise today's knowledge of e-cigarette health effects. He is currently working on something similar with IQOS and other heated tobacco products.

Questions

1. Generally, what temperature range do e-cigarettes vaporise the e-liquid?

- a. 57 to 66 degrees Celsius;
- b. 157 to 266 degrees Celsius;
- c. 200 to 400 degrees Celsius;
- d. 800 to 1000 degrees Celsius.

2. Which statement is true about the changes on the saliva because of e-cigarette usage?

- a. The pH of the saliva rises by the usage of nicotine-free liquids;
- b. The pH of the saliva decreases by the usage of nicotine-free liquids;
- c. The pH of the saliva rises by the usage of nicotine containing liquids;
- d. The vapour-induced temperature rise causes more saliva secretion.

3. According to a 2011 survey by the WHO, how many people used e-cigarettes regularly worldwide at the time?

- a. 1 million;
- b. 34 million;
- c. 7 million;
- d. 1 billion.

4. Which component of the e-liquid can cause yellowish-brownish patches on the surface of the teeth?

- a. Propylene-glycol;
- b. Glycerine;
- c. Sweeteners;
- d. Nicotine.

VIRTOPSY: A NEW DEVELOPING SCIENCE IN FORENSIC ODONTOLOGY

Rashmi GS Phulari^{1a*}, Bharvi Solanki^{1b}, Dharmesh Vasavada^{1c}¹Department of Oral and Maxillofacial Pathology and Microbiology, Manubhai Patel Dental College and Hospital, Maharaja Krishnakumarsinhji Bhavnagar University, Vadodara, Gujarat, India^aMDS, Professor and Head; e-mail: drashmi_g@mpdentalcollege.edu.in; ORCID-iD: <https://orcid.org/0000-0002-5023-2921>^bBDS, Postgraduate Student; e-mail: bharvis2020@mpdentalcollege.edu.in; ORCID-iD: <https://orcid.org/0000-0002-6212-8857>^cMDS, Reader; e-mail: drdharmesh_v@mpdentalcollege.edu.in; ORCID-iD: <https://orcid.org/0000-0003-2075-1920>

ABSTRACT

 [https://doi.org/10.25241/stomaedu.2022.9\(3-4\).art.6](https://doi.org/10.25241/stomaedu.2022.9(3-4).art.6)**Background** 'Virtopsy' is made up of two words 'virtual' and 'autopsy'. 'Virtual' means digitally available, while 'autopsy' means examination of deceased to find out the cause of death.**Objective** This review aims to provide an overall view about virtopsy in forensic odontology.**Data sources** A narrative review was performed with a literature search in the PubMed and Google Scholar electronic databases.**Study selection** Reference lists included full papers of any study design, published in peer-viewed English till June 2022.**Data extraction** Current literature indicates various methods and applications of virtopsy in forensic odontology. Moreover, recent advances in forensic odontology are discussed.**Data synthesis** Virtopsy is a virtual alternative to traditional autopsy. Conventional autopsy has its own pitfalls as it is an invasive procedure and not socially as well as emotionally accepted in certain religions. Virtual autopsy is a better adjunct for conventional autopsy. Virtual autopsy has its own advantages as digital storage of data can be done. Virtopsy used in forensic odontology is known as 'Virdentopsy'. Various equipment and robotic science have also developed in this field of Virdentopsy.

KEYWORDS

Dental autopsy; Forensic odontology; Human identification; Virdentopsy; Virtopsy

1. INTRODUCTION

In the field of medicine, conventional autopsy procedure has a mainstay role. It aids in establishing the final diagnosis, relates the cause of death to the associated pathologies as well as it explains the interaction between them. According to underlying purpose of this procedure, there are mainly 2 types of autopsies: Clinical and Forensic. Clinical autopsy is one which is performed in a clinical set up, by the pathologist with the positive consent of the family members of deceased to find out the cause of death. Forensic autopsy is performed in case of suspicious, violent, mass disaster or unknown cause of death [1]. Conventional autopsy is an invasive procedure which includes dissection, interpretation and cataloguing [2]. The corpse is handed over to family for last rituals after performing conventional autopsy procedure and thus, it is not possible to re-examine the decision if needed, while practicing conventional autopsy [3]. Sometimes, family of the deceased may not give consent for conventional autopsy owing to possible mutilation involved and also for certain religion believes [4,5]. These drawbacks of conventional autopsy led to genesis of emerging branch, virtual autopsy procedure, namely "Virtopsy" [6]. Because of the Covid-19 pandemic, the whole world


is being adjusting itself to the "new normal" things. Social distancing has become major part of day-to-day life as well as medical field. Thus, it is desirable to have every procedure touch-free and online during victim identification for forensic purposes as well. Virtopsy is a step forward in this direction. The research question formulated was 'Can virtopsy be equally efficient as conventional autopsy in forensic odontology?'. This literature review focuses on history, equipment, robotic science, methodology, application, advantages and disadvantages of virtopsy in forensic odontology.

2. METHODOLOGY

A literature search was performed for the narrative review in the PubMed and Google Scholar electronic databases. Reference list included full papers on the subject of virtopsy published in English language till June 2022.

3. RESULTS

Out of 30 references, 19 review articles, 5 original articles, 4 books, 1 case report and 1 active trademark are included. 10 review articles are concentrated in Indian subcontinents.

 **OPEN ACCESS** This is an Open Access article under the CC BY-NC 4.0 license.
Peer-Reviewed Article
Citation: Phulari RGS, Solanki B, Vasavada D. Virtopsy: a new developing science in forensic odontology. *Stoma Edu J.* 2022;9(3-4):115-119.**Received:** September 30, 2022; **Revised:** November 11, 2022; **Accepted:** November 23, 2022; **Published:** November 23, 2022.***Corresponding author:** Dr. Rashmi GS Phulari, MDS, Professor and Head of Department of Oral and Maxillofacial Pathology and Microbiology Address: Manubhai Patel Dental College, Vishwajyoti Ashram, Near Vidyakunj School, Munj mahuda, Vadodara 390011, Gujarat, India.**Tel./Fax:** +91 9601896824; **e-mail:** rashugs@rediffmail.com**Copyright:** © 2022 the Editorial Council for the Stomatology Edu Journal.

4. DISCUSSION

“Virtopsy” is combination of two terminologies ‘virtual’ and ‘autopsy’ [6]. Virtopsy can be employed for broad and systemic examination of whole body. As an alternative of conventional autopsy, virtopsy is less time consuming, aids better in final diagnosis and render respect to religious sentiments [7].

4.1 History

Way back to 3000 BCE, the ancient Egyptian civilization practised mummification, the removal and examination of internal organs of human for religious causes. In 44 BCE, after famous Julius Cesar’s murder by rival senator by stabbing him 23 times, his official autopsy was conducted. In 150 BC ancient Romans had established parameters for the legal practice of autopsy [8]. Dissections of dead bodies were done by Erasistratus and Herophilus to study organ and nerves [9]. “The seats and causes of disease” book including 700 autopsies performed by Giovanni & Morgagni was published in 1761 [10]. Credit for teaching autopsy as a part of medical education goes to William Osler (1800) [11]. German physicist Wilhelm Röntgen first discovered plain X-rays were on November 8, 1895. In 1999 first body scan was done for high-profile case using project names such as “digital-autopsy” or “scalpel-free autopsy” [12]. Prof. Richard Dirnhofer, the former head of Institute of Forensic Medicine of the University of Bern, Switzerland got registered trademark for the term ‘Virtopsy’ on 9th November 2001 [13].

4.2 Equipment for virtopsy in forensic odontology

Various types of records are used for virtopsy in forensic odontology. Digital Dental records are used to compare ante-mortem records with post-mortem records which aids in personal identification. Digital photography has a major role in practicing virtopsy in forensic odontology. It aids in cases involving identification, human abuse and most significantly, bite mark cases. Digital photography is essential for evidence collection and preservation which plays major role in future legal processing [14]. 3D digital scanning of bite marks enables accurate and fast recording of the bite marks in soft substances such as cheese, chocolate, pears, apples, and human skin without further distortion of the evidence during impression taking [15,16]. Exposure to pathogens can be minimized and several steps can be eliminated using digital scanner [17]. Computer-assisted overlays in bite-mark analysis is useful in case of personal assault and rape cases. It preserves 3D information in 2D. Digital dental radiography aids in dental practice as well as forensic odontology. It can be intraoral or extraoral radiography. It has advantages over conventional radiography such as lower exposure to radiation, ease of storing of images and elimination of chemical processing [18]. Digital dental radiographs can be used to find out if the victim had undergone any restorative or endodontic treatment. In most of the cases, it can serve as unique identity of an individual if ante-mortem records are present.

Computer Tomography-scan is used to examine hard tissues within the body: the teeth and skeleton. They are much easier to interpret than conventional radiographs as it shows two-dimensional views of three-dimensional objects. It helps in age estimation, identification, trauma analysis and disaster victim identification [19]. Magnetic Resonance imaging features soft tissue condition. Soft tissue changes can be identified with the help of MRI. It is used to explore the cause of death as an alternative to traditional autopsy [20]. 3D Surface Scanning photogrammetry is a science of making measurements using photographs. Numbers of photographs are taken from different angles and analysed by software [6]. Cone Beam Computed Tomography serves as a reliable source of evidence for ante-mortem and post-mortem records and assists in age estimation, gender determination and personal identification. Figure 1 shows equipments used for virtopsy in forensic odontology.

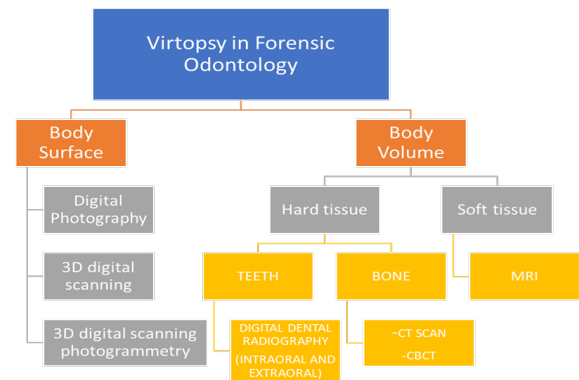


Figure 1. Equipments used for virtopsy in forensic odontology

4.3 Robotic science for virtopsy

Robotic science is used in many fields. Along with the conventional imaging techniques, robotic science can also be utilized to perform virtopsy. Many robotic smart devices such as Virtobot, Virto mobiles and smart glasses are used to perform virtopsy. Virtobot is an all-in-one machine. Virtobot is developed by PROFACTOR GmbH (SteyrGleink, Austria) according to Iso-9283: 1998. [21] It integrates the various imaging modalities to practice virtopsy. Within a single 3D space, combined surface and body volume acquisition can be done with Virtobot. With the help of Virtobot, interpersonal inaccuracies can be avoided [22]. They are gigantic machines of which their utility in field of disaster is not always feasible [6]. Virto mobiles are relatively new to this field dating from late 1990s to early 2000s [23]. Vitro mobiles are compact devices as compared to Virtobots. They work almost similar to Virtobots. They are mounted on a trailer which makes its transport easy at the site of disaster [24]. Smart glasses are also being used for practicing virtopsy. While one forensic expert examines the corpse wearing these glasses and team of forensic experts (who are not present at the site of disaster) can examine the same thing online on their respective computer devices [2]. Virtopsy table is a large touch-sensitive liquid crystal display screen. It represents the operating table

displaying the image of the body [19]. It was developed by Dr. Anders Perrson.

Virtopsy Table allows medical professionals to explore the inside of human body without need for invasive procedures. A large touch sensitive liquid-crystal display (LCD) screen represents the operating table displaying the image of the body. At the swipe of a finger, layers of skin and muscle are dissected. Also zooming in and out of the organs for their assessment and slicing through tissue using a virtual knife are possible [27]. Virtopsy table is well suited for medical training programs and police departments.

4.4 How to perform virtopsy?

Virtopsy includes 3D imaging techniques as well as 3D surface scan and all other digital recording techniques for mapping external surface of the body [26].

4.4.1 3D-Surface Scanning

With the help of virtobot, the corpse is first prepared. Virtobot places markers on exterior surface of the body accurately for the alignment of surface scan and interior scans more easily. After placement of markers, virtobot creates 3D colour model of corpse. Scan uses stereoscopic cameras to capture colour image. It takes 10 seconds for robot to move over the body and create 3D image.

4.4.2 3D-Imaging

After 3D surface scanning, the body (corpse) is double-covered inside a blue bag through which x-rays can easily pass through and it also prevents contamination, it respects privacy of deceased person, maintenance of hygiene and to remain undisturbed by non-forensic personal in room. X-ray, CT-scan, CBCT, MRI can be done. All data is then stored in computer.

Forensic odontologist can study the records anytime and images can be adjusted up and down & rotated at various angles, which provides flexibility which is absent in conventional autopsy.

4.4.3 Biopsy

After 3D surface scanning and 3D-imaging, needle biopsy can be done if internal body samples are needed. All data of biopsy also can be scanned and saved in computer.

4.5 Applications of virtopsy

The preliminary results, based on concept of 'Virtopsy' are promising enough. Radiological investigations can be used in Disaster Victim Identification in cases such as cranial, skeletal or tissue trauma. With the help of MSCT (Multi-slice computed tomography) and MRI, some forensic vital reactions can be diagnosed [12]. Applications of virtopsy include determining cause of death, gender & age determination in difficult forensic cases, identification of distinct foreign bodies and injuries, forensic 3D reconstructions, bullet tract identification, investigation of bite marks and for research purposes [27].

4.5.1 Determining the timing and cause of Death

MSCT and MRI can be used to determine timing of death in head injury cases.

4.5.2 For identification of individuals

Gender, age and personal identification is a challenge in difficult forensic cases. Disaster victim identification can be done using dental identification procedures by comparing post-mortem data with ante-mortem data, dental deoxyribonucleic acid techniques and development of dental post-mortem victim details.

Post-mortem dental data plays major role in dental identification. Visual examination is difficult in victims with charred bodies and damaged oral cavities. In such cases, virtopsy comes to our aid.

Smith et al. (2002) published a case report of positive identification of deceased individual which was accomplished by performing a CT scan on unidentified cranium and comparing multiple landmarks, images with corresponding features in an ante-mortem CT scan of a missing man [28].

4.5.3 For toxicological examination

In cases of drug abuse, Virtopsy can be used as a tool to determine the death of person.

4.5.4 Virtopsy in road traffic accidents and assaults

Post-mortem MSCT and MRI can be used in cases of fatal blunt head injury. Identification of foreign bodies, bullet tract can be done. 3D reconstruction of face can be done in case of completely mutilated bodies. Comparison of bite mark on human body or any other object can be done.

4.5.5 Virtopsy in hanging or manual strangulation

Post-mortem MSCT and MRI helps in identification of strangulation signs in victims of hanging or manual strangulation.

4.5.6 Virtopsy in death due to burns

Radiological methods of MSCT and MRI made it possible to document the injuries caused by burn as well as forensic relevant vital reactions (air embolism and blood aspiration).

Post-mortem imaging is a good forensic visualization tool with a great potential for forensic documentation of completely charred bodies.

4.6 Advantages [29,30]

- As it is a scalpel-free, it is a fast procedure
- It has a better social acceptance as it is a minimally invasive procedure
- Minimal risk of infection to the forensic experts and associated workers
- 3D analysis can be done
- Effective visualization and localization of fracture lines
- Depth of invasion of foreign body can be assessed
- Autopsy result with all the details can be digitally stored, thus amenable for re-examination and second opinion even after a long time
- Results will be observer independent

4.7 Disadvantages [29,30]

- Instruments and set-up used to practice biopsy are expensive
- Artefacts are difficult to identify
- Very fine structures cannot be studied
- Odour and colour change cannot be recorded
- Irregularity of body shape may affect screening
- Some loss of details can get while merging of data

Table 1. Difference between traditional autopsy and virtopsy.

TRADITIONAL AUTOPSY	VIRTOPSY
1. Invasive procedure and results in destruction of tissue.	1. Minimally invasive procedure and does not cause destruction of tissue.
2. Examination can only be done by experts present at the time of procedure.	2. Creates an objective 3D data set that can be shared with other experts who are not present at the time of procedure.
3. Less social acceptance	3. More social acceptance
4. Inter-observer variation can be present in results.	4. Results are independent of Inter-observer variation.
5. High risk of infection to experts & associated workers	5. Minimal risk of infection to experts & associated workers.
6. No digital storage of details. So, re-examination and second opinion cannot be done after long time.	6. Digital storage of details. So, re-examination and second opinion can be done even after long time.
7. Difficult to access depth of invasion of foreign body	7. Feasible to access depth of invasion of foreign body
8. Odour and colour change can be examined.	8. Odour and colour change cannot be examined.
9. Cost effective	9. Investment of expensive instruments is needed.

REFERENCES

- Costache M, Lazaroiu AM, Contolenco A, et al. Clinical or postmortem? The importance of the autopsy; a retrospective study. *Maedica*. 2014 Sep;9(3):261. PMID:PMC4305994 PMID:25705288
[Full text links PubMed Google Scholar](#)
- Lundberg GD. Low-tech autopsies in the era of high-tech medicine: Continued value for quality assurance and patient safety. *JAMA*. 1998 Oct 14;280(14):1273-1274. doi: 10.1001/jama.280.14.1273. PMID: 9786381.
[Full text links CrossRef PubMed Google Scholar Scopus WoS](#)
- Dirnhofer R, Jackowski C, Vock P, et al. VIRTOPSY: Minimally invasive, imaging-guided virtual autopsy. *Radiographics*. 2006 Sep-Oct;26(5):1305-33. doi: 10.1148/rg.265065001. PMID: 16973767.
[Full text links CrossRef PubMed Google Scholar Scopus WoS](#)
- França GV. *Legal Medicine*. 5th ed. Rio de Janeiro: Guanabara Koogan; 1998.
- Pomara C, Fineschi V, Scalzo G, Guglielmi G. Virtopsy versus digital autopsy: Virtual autopsy. *Radiol Med*. 2009 Dec;114(8):1367-1382. doi: 10.1007/s11547-009-0435-1. Epub 2009 Aug 7. PMID: 19669111.
[Full text links CrossRef PubMed Google Scholar Scopus WoS](#)
- Joseph TI, Girish KL, Sathyan P, et al. Virtopsy: An integration of forensic science and imageology. *J Forensic Dent Sci*. 2017 Sep-Dec;9(3):111-114. doi: 10.4103/jfo.jfds_52_16. PMID: 29657485; PMID: PMC5887631.]
[Full text links PubMed Google Scholar](#)
- Tejaswi KB, Hari Periya EA. Virtopsy (virtual autopsy): A new phase in forensic investigation. *J Forensic Dent Sci*. 2013 Jul;5(2):146-148. PMID: 24255565; PMID: PMC3826044.
[Full text links PubMed Google Scholar](#)
- Sinha PK, Gorea RK, Kumar P. Current scenario of virtopsy of head and neck. *J Indo Pacific Academy Forensic Odontology*. 2021;10(1):19-24.
[CrossRef](#)
- Bay NS, Bay BH. Greek anatomist herophilus: the father of anatomy. *Anat Cell Biol*. 2010 Dec;43(4):280-283. doi: 10.5115/acb.2010.43.4.280. Epub 2010 Dec 31. PMID: 21267401; PMID: PMC3026179.
[Full text links CrossRef PubMed Google Scholar](#)
- Ellis H. Matthew Baillie: Pioneer of systematic pathology. *Br J Hosp Med (Lond)*. 2011 Oct;72(10):594. doi: 10.12968/hmed.2011.72.10.594. PMID: 22041735.
[Full text links CrossRef PubMed Google Scholar Scopus WoS](#)
- Yogish P, Yogish A. Virtopsy: new phase in forensic odontology. *Int J Dent Health Sci*. 2015;2:1548-1555.
[Google Scholar](#)
- Badam RK, Sownetha T, Babu DBG, et al. Virtopsy: touch-free autopsy. *J Forensic Dent Sci*. 2017 Jan-Apr;9(1):42. doi: 10.4103/jfo.jfds_7_16. PMID: 28584475; PMID: PMC5450483.
[Full text links PubMed Google Scholar](#)
- VIRTOPSY - wirtschaft.ch - trademarks - Universität Bern Institut für Rechtsmedizin (IRM) Prof. Dr. R. Dirnhofer, Direktor Bern - Trademark no. P-491277 - Application no. 04728/2001. wirtschaft.ch. Retrieved 2013-08-28.
- Balaji N, Senapati S, Sumathi MK. Forensic digital photography: a review. *Int J Dent Med Res*. 2014;1(3):132-135.
[Google Scholar](#)
- Naether S, Buck U, Campana L, et al. The examination and identification of bite marks in foods using 3D scanning and 3D comparison methods. *Int J Legal Med*. 2012 Jan;126(1):89-95. doi: 10.1007/s00414-011-0580-7. Epub 2011 May 24. PMID: 21607716.
[Full text links CrossRef PubMed Google Scholar Scopus WoS](#)
- Stols G, Bernitz H. Reconstruction of deformed bite marks using affine transformations. *J Forensic Sci*. 2010 May;55(3):784-7. doi: 10.1111/j.1556-4029.2010.01337.x. Epub 2010 Mar 15. PMID: 20345800.
[Full text links CrossRef PubMed Google Scholar](#)
- Vilborn P, Bernitz H. A systematic review of 3D scanners and computer assisted analyzes of bite marks: searching for improved analysis methods during the Covid-19 pandemic. *Int J Legal Med*. 2022 Jan;136(1):209-217. doi: 10.1007/s00414-021-02667-z. Epub 2021 Jul 24. PMID: 34302214; PMID: PMC8302460.
[Full text links CrossRef PubMed Google Scholar Scopus WoS](#)
- Chiam SL. A note on digital dental radiography in forensic odontology. *J Forensic Dent Sci*. 2014; 6(3): 197-201. doi: 10.4103/0975-1475.137072. PMID: 25177144; PMID: PMC4142412.
[Full text links PubMed Google Scholar](#)
- Bassed R, Bott E. Application of post-mortem computed tomography to forensic odontology. In: Taylor JA, Kieser JA. *Forensic Odontology: Principles and Practice*. John Wiley & Sons, Ltd.;2016: 419-437. doi: https://doi.org/10.1002/9781118864418.ch14
[CrossRef Google Scholar](#)
- Ahmad MU, Sharif KA, Qayyum H, et al. Assessing the use of magnetic resonance imaging virtopsy as an alternative to autopsy: a systematic review and meta-analysis. *Postgrad Med J*. 2017 Nov;93(1105):671-678. doi: 10.1136/postgradmedj-2017-134945. Epub 2017 Jul 6. PMID: 28684530.
[Full text links CrossRef PubMed Google Scholar WoS](#)

5. CONCLUSION

Virtopsy emerges as a useful tool for forensic investigations. With the help of virtopsy, improved data collection can be made. Without damaging the body, one can visualize 3D anatomical structures thoroughly. After covid-era, absence of contamination from cadaver's substances is also beneficial for forensic experts' health. Computed approach in virtopsy provides the review of the case even after several years of death, improved data organization and communication between the forensic experts. Recently, the term VIDENTOPSY has been coined that merges the "virtual" and "dental autopsy". It is a registered brand by Nuzzolese E in 2021 with a dedicated website in order to offer a remote forensic odontological assessment of post mortem dental data of unidentified human remains.[25] Virtopsy still remains underused in forensic odontology requires further exploration to maximize its benefits to expand its space in dentistry.

CONFLICT OF INTEREST

The authors have certified that there is no conflict of interest.

AUTHOR CONTRIBUTIONS

RP, BS: reviewed articles. **RP, DV, BS:** critically revised revised the manuscript.

21. Ebert LC, Ptacek W, Naether S, et al. Virtobot -a multi-functional robotic system for 3D surface scanning and automatic post mortem biopsy. *Int J Med Robot*. 2010 Mar;6(1):18-27. doi: 10.1002/rcs.285. PMID: 19806611.
[Full text links](#) [CrossRef](#) [PubMed](#) [Google Scholar](#) [Scopus](#) [WoS](#)
22. Sathish S. Virtopsy: The digital era of autopsy. *Indian Journal of Forensic Odontology*. 2018;11(2):69-73. doi: http://dx.doi.org/10.21088/ijfo.0974.505X.11218.4
[Full text links](#)
23. Casey, Eoghan (2004). *Digital Evidence and Computer Crime*, Second Edition. Elsevier. ISBN 978-0-12-163104-8.
24. Rajendran R, Sivapathasundharam B. *Forensic Odontology*. Shafer's Textbook of oral pathology. 7th ed. India: Elsevier; 2012: 879-907.
25. Nuzzolese E. VIRDENTOPSY: virtual dental autopsy and remote forensic odontology evaluation. *Dent J (Basel)*. 2021 Sep 5;9(9):102. doi: 10.3390/dj9090102. PMID: 34562976; PMCID: PMC8468385.
[Full text links](#) [CrossRef](#) [PubMed](#) [Google Scholar](#) [Scopus](#) [WoS](#)
26. Thali MJ, Jackowski C, Oesterhelweg L, et al. VIRTOPSY - the Swiss virtual autopsy approach. *Leg Med (Tokyo)*. 2007 Mar;9(2):100-104. doi: 10.1016/j.legalmed.2006.11.011. Epub 2007 Feb 1. PMID: 17275386.
[Full text links](#) [CrossRef](#) [PubMed](#) [Google Scholar](#) [Scopus](#)
27. Navalkar AR. Virtopsy: a scalpel free autopsy-review of literature. *J Contemp Dent*. 2015; 5(3): 168-172. doi:10.5005/jp-journals-10031-1129
[CrossRef](#)
28. Smith DR, Limbird KG, Hoffman JM. Identification of human skeletal remains by comparison of bony details of the cranium using computerized tomographic (CT) scans. *J Forensic Sci*. 2002 Sep;47(5):937-939. PMID: 12353577.
[PubMed](#) [Google Scholar](#)
29. Patowary AJ. Virtopsy: one step forward in the field of forensic medicine- a review. *J Indian Acad Forensic Med*. 2008;30(1):32-36.
[Google Scholar](#)
30. Jeelani S, Baliah J. Virtopsy-a moral boon in forensics. *Journal of Scientific Dentistry*. 2020 Jul 30;3(1):54-58. doi: 10.5005/jsd-3-1-54
[CrossRef](#) [Google Scholar](#)

Rashmi GS PHULARI

Professor & Head of Department
 Oral and Maxillofacial Pathology and Microbiology
 Manubhai Patel Dental College and Hospital
 Vadodara, Gujarat, India



CV

Dr. Rashmi GS Phulari, Professor & Head of Department of Oral and Maxillofacial Pathology and Microbiology, Manubhai Patel Dental College and Hospital, Vadodara, Gujarat. She has authored a textbook titled 'Textbook of Dental Anatomy Physiology and Occlusion' and a monography titled 'Age Estimation in Forensic Odontology'. She has also published articles in several national and international indexed journals.

Questions

1. What is the purpose of performing autopsy?

- a. Clinical;
- b. Forensic;
- c. A and B both;
- d. None of the Above.

2. Which of the following is an invention of robotic science?

- a. Virtobot;
- b. 3D surface scanning;
- c. MRI;
- d. Intraoral radiographs.

3. Who registered the trademark for Virtopsy?

- a. Wilhelm Rongten;
- b. William Osler;
- c. Prof. Richard Dirnhofner;
- d. Giovanni & Morgagni.

4. Which of the following is not an advantage of Virtopsy?

- a. Better social acceptancel;
- b. Odor and color change can be recorded;
- c. 3D analysis can be done;
- d. Minimal risk of infection for the forensic experts and associated experts.

INTRODUCING DS PRIMETAPER™

THE PERFECT UNION OF FORM AND FUNCTION

DS PrimeTaper is a demonstration of science and art in harmony. With immediate function and intuitive digital workflows, these unique implants will complement and enhance your expertise.

-  EFFICIENT HANDLING
-  LASTING BONE CARE
-  ENVIABLE ESTHETICS
-  SEAMLESS WORKFLOW INTEGRATION



AN ANTERIOR RECONSTRUCTION: INCREASE THE OCCLUSAL VERTICAL DIMENSION OR REDUCE PERIODONTAL SUPPORT?

Jean-Philippe Ré^{1a*}, Jean-Daniel Orthlieb^{1b}, Anne Giraudeau^{1c}, Estelle Casazza^{1d}

¹Departement of Occlusodontology, School of Dental Medicine, Aix-Marseille University, Marseille, France

^aDDS, PhD, Associate Professor; e-mail: jeanphilippe.re@gmail.com; ORCIDiD : <https://orcid.org/0000-0002-3265-141X>

^bDDS, PhD, Professor; e-mail: jdorthlieb@orange.fr; ORCIDiD : <https://orcid.org/0000-0002-8565-8922>

^cDDS, Associate Professor; e-mail: anne.giraudeau@free.fr; ORCIDiD : <https://orcid.org/0000-0001-8363-5367>

^dDDS, Assistant Professor; e-mail: estelle.casazza@gmail.com; ORCIDiD : <https://orcid.org/0000-0002-3316-7267>

ABSTRACT

[https://doi.org/10.25241/stomaedu.2022.9\(3-4\).art.7](https://doi.org/10.25241/stomaedu.2022.9(3-4).art.7)

Aim The aim was to document a clinical situation which was managed at minimal biological cost and with straightforward implementation.

Summary Challenges of space management may arise in prosthetic dentistry as a minimum height is needed for the supporting tissues and the restorative material.

While increasing the vertical occlusal dimension allows an increase in the height of the prostheses, the option may be complex and has disadvantages, including the need to modify the entire occlusion. Crown lengthening is an alternative therapeutic option, but it results in a decrease in periodontal support. Nevertheless, it allows less extensive prostheses to be provided without impacting the rest of the arch. Managing complex clinical situations with moderate biological cost and straightforward implementation is possible, as illustrated in this clinical report.

Key learning points

1. Crown lengthening is a solution to increasing the tooth surfaces necessary at prosthetic rehabilitation.
2. Increasing occlusal vertical dimension (OVD) is a solution to providing the occlusal space necessary for the restorative material without reducing the supporting tissues.
3. Crown lengthening reduces periodontal support but can be considered when the root length of the affected teeth is sufficient.
4. Increasing the OVD requires modification of the entire occlusion.
5. Crown lengthening offers the advantage of not modifying OVD or intercuspal position (ICP).

KEYWORDS

Crown Lengthening; Deep Bite; Prosthodontic Treatment Planning; Dental Occlusion; Therapeutic Decision

1. INTRODUCTION

The management of dental wear is frequently encountered in prosthodontic practice [1]. Interventions can range from straightforward lifestyle advice to complete-mouth rehabilitation [2]. While contemporary dentistry advocates the conservation of tooth structure and pulpal vitality [3] and the application of adhesive dentistry with minimal tooth preparation [4], complete-mouth rehabilitation typically involves extensive tooth preparation. The purpose of this clinical report was to document a clinical situation which was managed at minimal biological cost and with straightforward implementation.

her smile (Fig. 1). However, she wished to avoid extensive or invasive procedures and categorically declined orthodontic treatment such as intrusion of the front teeth.

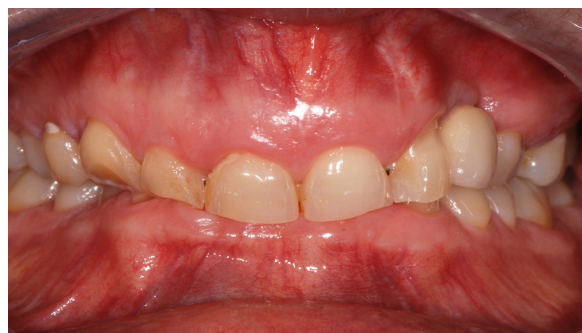

Figure 1A. Pretreatment: (A) Intercuspal position.

2. CASE PRESENTATION

A 76-year-old woman sought treatment in 2011 because she was concerned about the wear of her mandibular anterior teeth which were sensitive to cold, leading to mastication difficulties, and also because the patient's chief concern was to improve

Clinical examination showed, on palpation, large and dense masseter muscles but less complaints from the patient, suggesting oral habits like frequent parafunctional muscle activity, observed by family

OPEN ACCESS This is an Open Access article under the CC BY-NC 4.0 license.

Peer-Reviewed Article

Citation: Ré JP, Orthlieb JD, Giraudeau A, Casazza E. An anterior reconstruction: increase the occlusal vertical dimension or reduce periodontal support?. *Stoma Edu J.* 2022;9(3-4):121-124.

Received: March 27, 2022; **Revised:** April 11, 2022; **Accepted:** April 20, 2022; **Published:** May 17, 2022.

***Corresponding author:** Jean-Philippe Ré; Departement of Occlusodontology, School of Dental Medicine, Aix-Marseille University, Marseille, France Address: 27, Boulevard Jean Moulin, 13355 Marseille Cedex 5, France, **Tel.:** +33494923491; **Fax:** +33494910965; **e-mail:** jeanphilippe.re@gmail.com

Copyright: © 2022 the Editorial Council for the Stomatology Edu Journal.

members. She had a reproducible, stabilized, and nondeflected intercuspal position (ICP), despite worn incisors and mandibular canines. The posterior teeth were in good condition and unrestored, were in good alignment, and had a seemingly unaltered occlusal vertical dimension (OVD). She had group function eccentric guidance on the right side and canine disclusion on the left side. Some mandibular anterior teeth were worn almost to the gingival margin, with the dental pulp almost exposed by wear (Fig. 1B). The maxillary incisors and canines also showed wear, and the location of their gingival margins suggested extrusion. The maxillary incisors completely overlapped the mandibular incisors in the intercuspal position (ICP). (Fig. 1A) The periodontal examination, with normal probing depth and zone of attached gingiva, and the radiological examination did not reveal any periodontal lesions and none of the teeth had received or required endodontic treatment. The teeth had roots of normal size, and the left maxillary canine had been replaced by an implant-supported crown a few years previously. (Fig. 1C) The skeletal and dental relationships were Angle class I with normal mandibular movements, with no temporomandibular joint (TMJ) sounds or complaints from the patient. In addition, the patient had no medical history of gastroesophageal reflux disease, xerostomia, consumption of excess acidic soft drinks and her conventional diet habits did not appear to affect the anterior teeth.

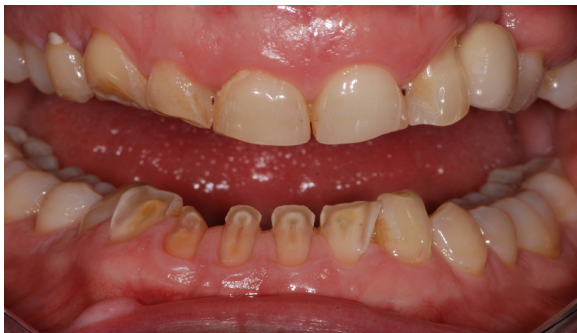

Figure 1B. Pretreatment: Extensive wear particularly on anterior mandibular teeth and more extensive on the right side.

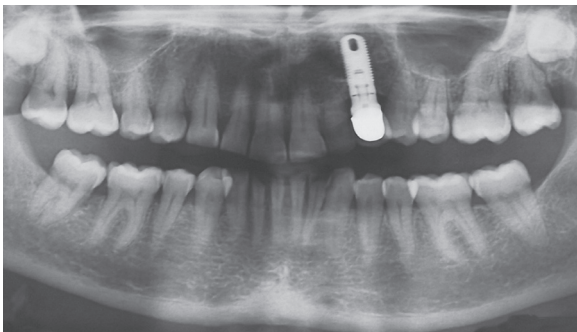


Figure 1C. Pretreatment: Initial panoramic radiograph.

A diagnosis of bruxism (including attrition) was made with increased occlusal loading of the anterior teeth. Complete restoration of the anterior teeth was indicated to address esthetic [5], sensitivity, and functional concerns and also to preserve these teeth from further damage.

The treatment plan involved the reconstruction of the anterior teeth to recreate the correct anatomy of the maxillary and mandibular incisors and canines and to restore the anterior vertical and horizontal overlaps, approaching average values of 3 to 4 mm with optimized mandibular function [6]. A major difficulty was the lack of space available at the anterior sector; the maxillary and mandibular gingiva appeared to meet in the frontal plane in the ICP (Fig. 1A).

The mandibular incisors and the right canine teeth had minimal coronal height, and enamel was almost entirely missing. The left mandibular canine was intact but was extruded above the occlusal plane. The mandibular and maxillary anterior teeth required restoration, and the maxillary anterior teeth also needed reshaping to correct their extrusion. Various treatment options were considered, but first the occlusal vertical dimension (OVD) was considered. An increase in the OVD would minimize the preparation of the maxillary anterior teeth and provide the occlusal space necessary to restore the coronal anatomy of the mandibular anterior teeth. However, an increase in OVD would require restoration of the posterior occlusion. In addition, esthetics would be compromised with the lengthened maxillary posterior teeth.

Because the posterior teeth were unrestored and in good functional occlusion, her existing OVD was preserved.

Bonded anterior ceramic restorations were problematic in the absence of sufficient enamel to ensure a durable and effective adhesion [7]. However, cemented ceramic crowns were also problematic because of the lack of resistance and retention form. Maintaining her OVD and intercuspal position (ICP) required the exposure of sufficient tooth structure to provide resistance form.

This could only be achieved by reducing the periodontal support with maxillary and mandibular anterior crown lengthening [8]. Crown lengthening and retaining OVD and ICP created sufficient resistance and retention, at least 4 mm in height (Fig. 2) [9].

Also, respecting the interproximal papillary area, the gingival margins of the anterior teeth were aligned with those of the posterior teeth to improve esthetics.

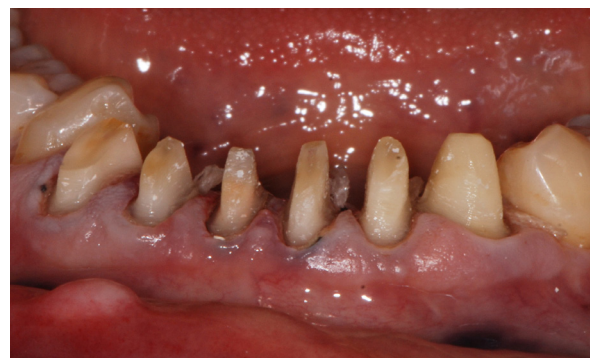

Figure 2A. Tooth preparations 3 months after crown lengthening: Mandibular

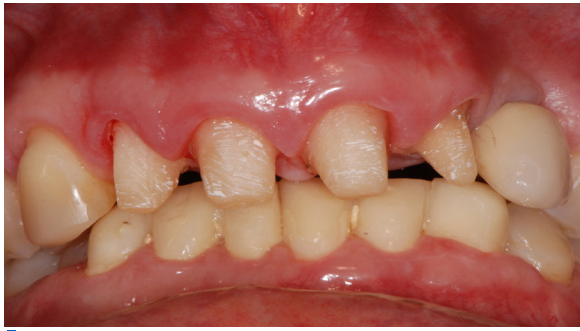

Figure 2B. Tooth preparations 3 months after crown lengthening: Maxillary

Ceramic crowns (IPS e.max Press MO, A3 shade; Ivoclar Vivadent) with minimal tooth preparation were provided, although 2 teeth required endodontic treatment (Fig. 3).

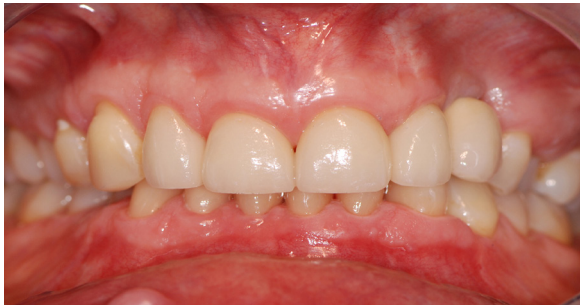

Figure 3A. After treatment: Clinical photograph showing harmonious smile line and occlusion.

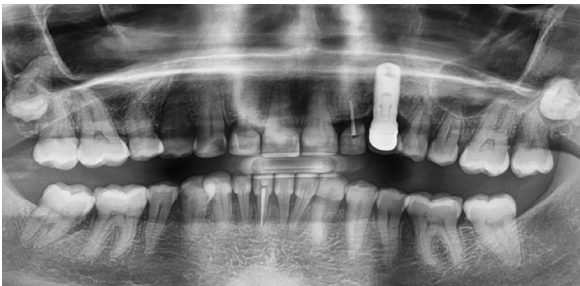

Figure 3B. After treatment: Panoramic radiograph, two teeth required endodontic therapy.

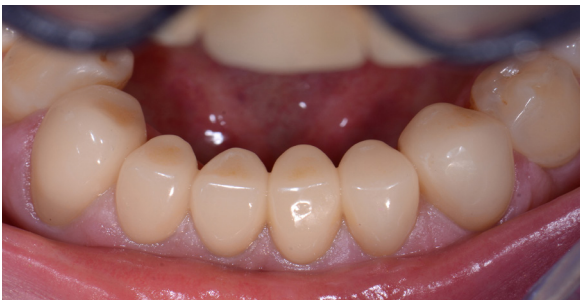

Figure 3C. After treatment: Mandibular occlusal view.

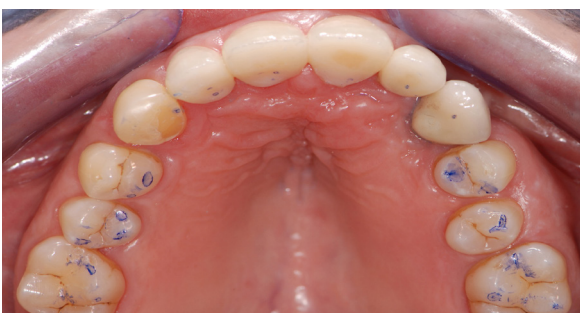

Figure 3D. After treatment: Maxillary occlusal view.

A recall appointment after 11 years confirmed that the patient's complaints (wear, sensitivity, function, and esthetics) had been addressed and that crown lengthening instead of an increase in OVD was an appropriate choice (Fig. 4).

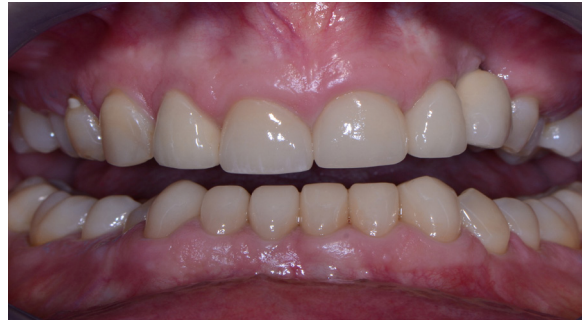

Figure 4. Eleven years after treatment.

3. DISCUSSION

Clinical situations may require deciding between the need for space management to accommodate the restorative material or reducing the supporting tissues. Crown lengthening is a solution to increasing the tooth surfaces necessary and increasing OVD is a solution to providing the occlusal space necessary for the restorative material without reducing the supporting tissues.

Crown lengthening reduces periodontal support but can be considered when the root length of the affected teeth is sufficient and reduces the prosthetic dentistry required. It offers the advantage of not modifying OVD or ICP and therefore simplifies the prosthetic treatment. Increasing the OVD should be reserved for complete dental arch rehabilitation. It is more complex because it requires modification of the entire occlusion

4. DISCUSSION

A 76-year-old woman patient sought treatment in 2011 because her mandibular anterior teeth were worn, sensitive to cold, nonfunctional and unesthetic. Despite a complex clinical situation caused by the extrusion of the maxillary anterior teeth causing a lack of space in the anterior teeth, the posterior teeth were in good condition. Crown lengthening of the anterior teeth was chosen to simplify treatment, without an increase in OVD, which meant that the entire occlusion did not have to be modified. Clinical follow-up at 11 years, accompanied by behavioral counselling but without splint therapy, confirmed the durability of a classic prosthetic treatment, despite the development of new techniques, and that the patient's concerns had been addressed.

ACKNOWLEDGMENTS

None.

AUTHOR CONTRIBUTIONS

JPR, AG, EC: wrote the manuscript in consultation with **JDO**. All authors provided critical feedback and helped shape the manuscript.

REFERENCES

1. Rees JS, Somi S. A guide to the clinical management of attrition. *Br Dent J.* 2018;224(5):319-323. doi: 10.1038/sj.bdj.2018.169. PMID: 29495028.
[Full text links](#) [CrossRef](#) [PubMed](#) [Google Scholar](#) [Scopus](#) [WoS](#)
2. O'Toole S, Pennington M, Varma S, Bartlett DW. The treatment need and associated cost of erosive tooth wear rehabilitation - a service evaluation within an NHS dental hospital. *Br Dent J.* 2018;224(12):957-961. doi: 10.1038/sj.bdj.2018.444. PMID: 29880974.
[Full text links](#) [CrossRef](#) [PubMed](#) [Google Scholar](#) [Scopus](#) [WoS](#)
3. Lam CW, Wilson PR. Crown cementation and pulpal health. *Int Endod J.* 1999;32(4):249-256. doi: 10.1046/j.1365-2591.1999.00218.x. PMID: 10551117.
[Full text links](#) [CrossRef](#) [PubMed](#) [Google Scholar](#) [Scopus](#) [WoS](#)
4. Tirlet G, Crescenzo H, Crescenzo D, Bazos P. Ceramic adhesive restorations and biomimetic dentistry: tissue preservation and adhesion. *Int J Esthet Dent.* 2014;9(3):354-369. PMID: 25126616.
[Full text links](#) [PubMed](#) [Google Scholar](#) [Scopus](#)
5. Dym H, Pierre R 2nd. Diagnosis and Treatment Approaches to a "Gummy Smile". *Dent Clin North Am.* 2020;64(2):341-349. doi: 10.1016/j.cden.2019.12.003. PMID: 32111273.
[Full text links](#) [CrossRef](#) [PubMed](#) [Google Scholar](#) [Scopus](#)
6. Brunelle JA, Bhat M, Lipton JA. Prevalence and distribution of selected occlusal characteristics in the US population, 1988-1991. *J Dent Res.* 1996;75 Spec No:706-13. doi: 10.1177/002203459607502510. PMID: 8594094.
[Full text links](#) [CrossRef](#) [PubMed](#) [Google Scholar](#) [Scopus](#) [WoS](#)
7. Swift EJ Jr, Perdigão J, Heymann HO. Bonding to enamel and dentin: a brief history and state of the art, 1995. *Quintessence Int.* 1995;26(2):95-110. PMID: 7568728.
[PubMed](#) [Google Scholar](#) [Scopus](#)
8. Verardi S, Ghassemian M, Bazzucchi A, Pavone AF. Gummy smile and short tooth syndrome - part 2: periodontal surgical approaches in interdisciplinary treatment. *Compend Contin Educ Dent.* 2016;37(4):247-251; quiz252. PMID: 27136119.
[PubMed](#) [Google Scholar](#) [Scopus](#)
9. Santos Pantaleón D, Morrow BR, Cagna DR, et al. Influence of remaining coronal tooth structure on fracture resistance and failure mode of restored endodontically treated maxillary incisors. *J Prosthet Dent.* 2018;119(3):390-396. doi: 10.1016/j.prosdent.2017.05.007. PMID: 28756865.
[Full text links](#) [CrossRef](#) [PubMed](#) [Google Scholar](#) [Scopus](#) [WoS](#)

Jean-Philippe RÉ

DDS, PhD, Associate Professor
 Department of Occlusodontology
 School of Dental Medicine
 Aix-Marseille University
 Marseille, France



CV

Dr. Ré, DDS, PhD has been an occlusodontist and Associate Professor at the Department of Oral Functions/Dysfunctions, School of Dental Medicine, Aix-Marseille University, France since 2008. He runs a private practice oriented to prosthodontics in Toulon. He is good at treating prosthetic patients, especially complex case treated with the multidisciplinary approach. He authored the book titled "Orthèses orales".

Questions

1. What is the recommendation of contemporary dentistry?

- a. No conservation of teeth;
- b. No conservation of pulpal vitality;
- c. Extensive tooth preparation;
- d. Adhesive dentistry.

2. What is the diagnosis of dental wear?

- a. Bruxism;
- b. Absence of gastroesophageal reflux disease;
- c. Absence of consumption of excess acidic soft drinks;
- d. Conventional diet habits.

3. What is the consequence of dental crown lengthening?

- a. Cannot be a solution to increasing the tooth surfaces necessary for prosthetic retention;
- b. Reduces periodontal support;
- c. Alters OVD or ICP;
- d. Cannot be sectorial.

4. What is the consequence of increasing OVD?

- a. Does not avoid reducing the supporting tissues;
- b. Should be reserved only for complete both dental arches rehabilitation;
- c. Requires modification of the entire occlusion;
- d. Is not a solution to provide the occlusal space necessary for the restorative material.


Made by You

Dentsply Sirona CEE Central
Office & Showroom
Str. Vulturilor 98A, 030857, București
Tel.: 0774 074 094
office.romania@dentsplysirona.com
www.dentsplysirona.ro
<https://facebook.com/dentsplysirona.romania>

Open a world of confident smiles with Primescan's uniquely accurate approach to dentistry. Primescan as unique as your patients, the first intraoral scanner to be validated for Atlantis suprastructures.



Scanned with Primescan



Because every bite is different.



Bausch
WE MAKE OCCLUSION VISIBLE

Dr. Jean Bausch GmbH & Co. KG | Oskar-Schindler-Str. 4 | D-50769 Cologne | Germany
Phone: +49-221-70936-0 | info@bauschdental.de | www.bauschdental.de

THE MAGDENT - MED DEVICE ENSURES AN INCREASE IN THE HEALING RATE OF DENTAL IMPLANT PROCEDURES

Titanium dental implants are widely used in dentistry to restore single to total dentition. Despite the new improvements brought to them, the healing period in which the implants should remain unloaded is 3-6 months.

It has been demonstrated that a pulsed electromagnetic field (PEMF) contributes to the increase of bone regeneration in a number of clinical fields, including dentistry.

Recently, a miniaturized electromagnetic device (MED) was introduced into the therapeutic arsenal, which fits most dental implants. MED is shaped as a simple healing abutment, it is easily screwed into the implant and removed at the end of the treatment period.

The Magdent-MED device consists of a battery, an electronic device and a coil that fits most implant designs in the same way as current single healing abutments.


The MED is made of Ti-6Al-4V and is shaped like a healing slip with a 1.25mm (0.05") hex socket. The device is installed according to the usual protocols for the use of healing abutments, except that the MED must be activated with an Activator before it is installed inside the implant.

Similar to simple healing abutments, MED is designed for single use. Before activation, MED can be stored for up to 18 months. Once activated, the MED battery will generate an electromagnetic field for up to 30 days. MED comes in a variety of designs to fit different brands and models of dental implants.

According to the manufacturer of the MED device, it has the following advantages:

- * 300% acceleration of the healing process
- * 48% bone to implant growth (BIC)
- * 62% increase in trabecular bone density
- * 60% improvement in bone quality
- * The best solution for patients with poor bone quality, autoimmune diseases, as well as heavy smokers.

According to the studies presented in the literature, I recommend the use of the Magdent-MED device to increase the success rate of implant procedures and to increase the satisfaction of the dental implant patient.



The Magdent-MED device from Magdent Inc.

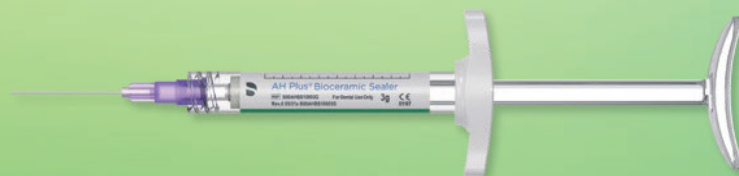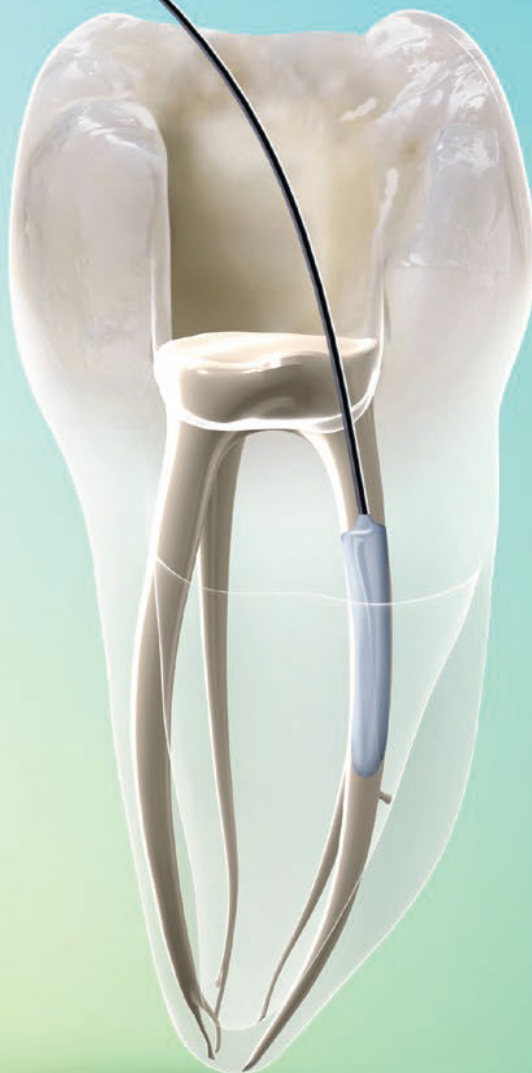<https://magdentmed.com/products/>
www.magdent.co.il

Florin - Eugen Constantinescu
 DMD, PhD Student
 Editorial Director, Product News

 [https://doi.org/10.25241/stomaedu.2022.9\(3-4\).prodnews.1](https://doi.org/10.25241/stomaedu.2022.9(3-4).prodnews.1)

AH Plus® Bioceramic Sealer

**Ready,
SET, Go!**



 Dentsply
Sirona

Dentsply Sirona CEE Central
Office & Showroom
Str. Vulturilor 98A, 030857, Bucuresti
Tel.: 0774 074 094
office.romania@dentsplysirona.com
www.dentsplysirona.ro
http://facebook.com/dentsplysirona.romania

It is all about passion.

Benefit from the advantages of a bioceramic sealer, providing an ideal environment for Hydroxyapatite formation paving the way for the body's self healing process and set your new standard with AH Plus® Bioceramic Sealer.

dentsplysirona.com/bioceramic-sealer #EndoPassion


PART OF A



Color Science and Shade Selection in Operative Dentistry

Essential Elements for Clinical Success

Editors: Dayane Oliveira
 Publisher: Springer Nature, Switzerland
 Language: English
 ISBN: 978-3-030-99172-2
 Edition: 1/e
 Publish Year: 2022
 Pages: 142, Illustrated
 Price: € 160,49



**Marian-Vladimir
 Constantinescu**

DDS, MSc, PhD
 Holistic Dental & Medical Institute
 of Bucharest - ROPOSTURO
 Bucharest, Romania
 e-mail: dr.vladimir.constantinescu@gmail.com

Books Review

Dr. Dayane Oliveira, as editor and author along with 17 co-authors offers the reader a book on shade selection in Esthetic and Restorative Dentistry, a book entitled **"Color Science and Shade Selection in Operative Dentistry"**. The 10 chapters of the book present the practitioner with essential elements for clinical success in shade selection in Dentistry.

The book begins by reviewing colour science, colour definition, colour and its dimensions (hue, value, chroma and translucency) and discussing colour perception (light, object and observer). It then presents the optical properties of natural teeth, composition of the natural teeth structures, optical properties of the tooth structure and optical properties of the resin composites, composition and optical properties (translucency, fluorescence and opalescence and counter-opalescence). Colour selection in operative dentistry is thoroughly explained and suggestively illustrated by methods of illumination and colour selection for composite restorations.

Descriptions of visual colour evaluation methods such as Ishihara vision testing chart and colour perception x colour acceptance thresholds, digital methods to evaluate colour and experimental designs to evaluate colour support colour evaluation for research purposes.

Knowledge of the various types of digital cameras used in dentistry, photographic equipment and accessories, as well as the fundamentals of dental photography: exposure square, grey card, cross-polarisation, communication with the laboratory are a key to clinical success in daily dental practice. Teeth whitening techniques and color measurement are described to better understand whitening procedures. Presentation of build-up layering techniques and restoration planning using schematic drawings provide insights into natural tooth biomimetics using composites. Finishing and polishing composite restorations are an essential procedure for the longevity of the restoration and the tooth.

Shade change in resin composite restorations, methods of minimizing discoloration, methods of correcting discoloration are also presented.

Finally the longevity of aesthetic composite restorations, reasons for failure and exploration of repair of defective restorations as a treatment option at replacement are discussed.

With its enlightening content, this book is a useful guide to the science of color and shade selection in dentistry so that the practitioner can achieve consistent clinical success.

The book entitled **"Color Science and Shade Selection in Operative Dentistry"** is aimed at practitioners in restorative and aesthetic dentistry, but is also useful for students and researchers in the field of dentistry

 [https://doi.org/10.25241/stomaedu.2022.9\(3-4\).bookreview.1](https://doi.org/10.25241/stomaedu.2022.9(3-4).bookreview.1)

The Books Review is drafted in the reviewer's sole wording and illustrates his opinions

Florin-Eugen Constantinescu
DMD, PhD Student
Holistic Dental & Medical Institute
of Bucharest - ROPOSTURO
Bucharest, Romania
e-mail: dr.florin.constantinescu@gmail.com

Digital Dental Implantology

From Treatment Planning to Guided Surgery

Editors: Jorge M. Galante, Nicolás A. Rubio
Publisher: Springer Nature, Switzerland
Language: English
ISBN: 978-3-030-65946-2
Edition: 1/e
Publish Year: 2021
Pages: 210, Illustrated
Price: € 139,09



Dr. Jorge M. Galante, professor at Universidad de Buenos Aires and Universidad del Salvador and Dr. Nicolás Agustín Rubio, professor at Universidad de Buenos Aires, Universidad del Salvador and ROCA International, present their experience on oral rehabilitation with oral implants in the book entitled **“Digital Dental Implantology”** which has 10 chapters.

This book describes the fusion of two technologies, namely CBCT and CAD/CAM aimed at providing surgical dental treatments and explains the advantages and applications of this digital approach for implant placement procedures and other oral surgical protocols.

All aspects of computer-aided imaging and design are first covered in the textbook, including the creation of DICOM and STL files, followed by the process of virtual merging to obtain a combined image. Secondly, clinical tips for the use of digital wax up, software interactions and accurate template fabrication are explained, including subtractive and additive methods used for this manufacturing step. The other chapters are devoted to the application of technology fusion in implantology, guided bone regeneration, and maxillofacial surgery. Both static and dynamic guided surgeries are described. Materials characteristics and surgical instruments are also presented to define the correct selection criteria.


The digital approach outlined in this textbook involves a paradigm shift in the way traditional oral surgery is conceived. Technology fusion aims to improve treatment accuracy, optimize clinical time and reduce patient morbidity. Clinicians will find this book to be a valuable guide for virtual surgical planning and a path taking them into the exciting world of digital dental surgery.

The Books Review is drafted in the reviewer's sole wording and illustrates his opinions

 [https://doi.org/10.25241/stomaeduj.2022.9\(3-4\).bookreview.2](https://doi.org/10.25241/stomaeduj.2022.9(3-4).bookreview.2)

Integrated Procedures in Facial Cosmetic Surgery

Editors: Seied Omid Keyhan, Tirbod Fattahi,
 Shahrokh C. Bagheri, Behnam Bohluli,
 Mohammad Hosein Amirzade-Iranaq
 Publisher: Springer Nature, Switzerland
 Language: English
 ISBN: 978-3-030-46992-4
 Edition: 1/e
 Publish Year: 2021
 Pages: 1011, Illustrated
 Price: € 299,59



**Marian-Vladimir
Constantinescu**

DDS, MSc, PhD
 Holistic Dental & Medical Institute
 of Bucharest - ROPOSTURO
 Bucharest, Romania
 e-mail: dr.vladimir.constantinescu@gmail.com

Books Review

This book have been drafted by some of the best-known and professional maxillofacial surgeons, plastic surgeons, and otolaryngologists from all over the world.

"Integrated Procedures in Facial Cosmetic Surgery" has twelve parts and seventy-three chapters. The book first presents the history of plastic surgery and the importance of a multidisciplinary approach.

The second part is about principles and baselines like facial aesthetic units, facial analysis and clinical evaluation charts, principles of facial photography, and the anatomic basis of facial surgical complications.

It then presents the facial bone contouring: genioplasty, malarplasty, mandibular angle reduction and augmentation, frontal bossing reduction, facial prosthesis: conventional methods versus 3D concepts and others. A remarkable advantage of this book is its Q/A Discussion chapters. In These chapters discuss the opinions, approaches, and experiences of current legendary pioneer surgeons in the field of facial cosmetic surgery regarding the present trending topics in this field.

The following parts focus on procedures as: rhinoplasty, cleft lip and plate, blepharoplasty, lifting procedures, orthognathic surgery, intra-oral plastic surgeries.

Office-based procedures are explained in detail and it helps you understand the application of soft tissue filler in the oral and maxillofacial field, fat transfer and facial lipofilling, chemical peeling, the CO 2 laser, HIFU and RF therapy in facial rejuvenation and hair restoration.

Overall, it is a comprehensive and manageable book in facial cosmetic surgery that includes a large number of new techniques in this specific field.

This book provides the reader with a compendium of fundamental principles with over 900 original photographs, fully illustrating each procedure in a stepwise manner and will also be of interest to dentists, prosthodontists, periodontists, radiologists, general surgeons, and dermatologists.

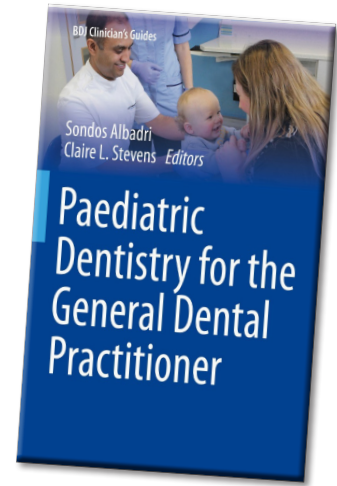
 [https://doi.org/10.25241/stomaedu.2022.9\(3-4\).bookreview.3](https://doi.org/10.25241/stomaedu.2022.9(3-4).bookreview.3)

The Books Review is drafted in the reviewer's sole wording and illustrates his opinions

Iulia Ciolachi
DMD
Holistic Dental & Medical Institute
of Bucharest - ROPOSTURO
Bucharest, Romania
e-mail: dr.iuliaciolachi@yahoo.ro

Paediatric Dentistry for the General Dental Practitioner

Editors: Sondos Albadri, Claire L. Stevens
Publisher: Springer Nature, Switzerland
Language: English
ISBN: 978-3-030-66371-1
Edition: 1/e
Publish Year: 2021
Pages: 330, Illustrated
Price: € 149,79



Dr. Sondos Albadri, Professor and Honorary Consultant in Paediatric Dentistry at the University of Liverpool and Dr. Claire L. Stevens, Consultant in Paediatric Dentistry at the Manchester University provides us with a comprehensive guide to the management of children and adolescents in general dental practice entitled "**Paediatric Dentistry for the General Dental Practitioner**".

The book addresses oral health based on evidence, comprises 15 chapters and is divided into four sections, focusing on a specific age group, helping the reader to relate clinical problems to the different stages of dental development.

Common oral and dental problems and their diagnosis and treatment, dental caries, dental trauma, developmental abnormalities, periodontal problems and soft tissue disorders are covered in detail throughout. Updated guidance on history taking, dental examination, preventive strategies, and advanced behavioral management is presented. In addition, the relevance of common medical conditions to day-to-day dental management is discussed. To better understand the content, the text is supported by many informative and diagrams.

The book "**Paediatric Dentistry for the General Dental Practitioner**" is a detailed and comprehensive treatise on the management of the pediatric dental patient addressed to dental therapists, the dental foundation and junior trainees.


 [https://doi.org/10.25241/stomaedu.2022.9\(3-4\).bookreview.4](https://doi.org/10.25241/stomaedu.2022.9(3-4).bookreview.4)

The Books Review is drafted in the reviewer's sole wording and illustrates his opinions

Functional Biomaterials

Drug Delivery and Biomedical Applications

Editors: Sougata Jana, Subrata Jana
Publisher: Springer Nature, Switzerland
Language: English
ISBN: 978-981-16-7151-7
Edition: 1/e
Publish Year: 2022
Pages: 522, Illustrated
Price: € 235,39



Florin-Eugen Constantinescu
DMD, PhD Student
Holistic Dental & Medical Institute
of Bucharest - ROPOSTURO
Bucharest, Romania
e-mail: dr.florin.constantinescu@gmail.com

Books Review

Dr. Sougata Jana of the Department of Health and Family Welfare, Directorate of Health Services, Kolkata, India and Associate Professor Subrata Jana of the Department of Chemistry, Indira Gandhi National Tribal University, Amarkantak, India present functional biomaterials based systems for drug delivery and biomedical approaches throughout 18 chapters.

The chapters of the "**Functional Biomaterial**" book cover the latest technologies, such as polymeric micelles, pH-sensitive biomaterials, stimuli-responsive hydrogels, silk fibroin, inorganic biomaterials, synthetic biomaterials, 3D printed biomaterials, metallic biomaterials, ceramic and hybrid biomaterials. Theranostic approaches for cancer therapy, biomaterial-based nanofiber scaffolds in tissue engineering, as well as application strategies of metallic biomaterials for medical and dental prosthetics are also described.

The book "**Functional Biomaterials**" by Dr. Sougata Jana and Associate Professor Subrata Jana, as editors and the 63 contributors is an updated approach in materials science regarding the development of new drug delivery strategies. The book is a notable reference for researchers and professionals working in biomaterials research in the pharmaceutical and medical fields.

 [https://doi.org/10.25241/stomaeduj.2022.9\(3-4\).bookreview.5](https://doi.org/10.25241/stomaeduj.2022.9(3-4).bookreview.5)

The Books Review is drafted in the reviewer's sole wording and illustrates his opinions

**Marian-Vladimir
Constantinescu**

DDS, MSc, PhD
Holistic Dental & Medical Institute
of Bucharest - ROPOSTURO
Bucharest, Romania
e-mail: dr.vladimir.constantinescu@gmail.com

Innovative Perspectives in Oral and Maxillofacial Surgery

Editors: Mark R. Stevens, Shohreh Ghasemi, Reza Tabrizi
Publisher: Springer Nature, Switzerland
Language: English
ISBN: 978-3-030-75749-6
Edition: 1/e
Publish Year: 2021
Pages: 499, Illustrated
Price: € 117,69



Dr. Mark Stevens, Chief of the Department of Oral and Maxillofacial Surgery at Augusta University in Augusta, GA, USA, Dr. Shohreh Ghasemi, Resident of oral surgery at the International University of Catalonia in Barcelona, Spain and Dr. Reza Tabrizi, Associate professor of Shahid Behshiti University of Medical Sciences in Tehran, Iran as editors together with the 87 contributors are creating a book on the latest technologies and developments in oral and maxillofacial surgery. The book entitled "**Innovative Perspectives in Oral and Maxillofacial Surgery**" addresses the proposed topic in 52 chapters.

This book examines the latest technologies and developments in oral and maxillofacial surgery. Information is presented in an easy-to-read format and each surgical technique is detailed. Each chapter includes scientific documentation of the procedure through clinical trials, objective patient benefits, detailed explanations of the procedure, levels of treatment complexity according to the SAC (simple-advanced complex) classification, and costs.

First, it starts with information on osteocyte, molecular and cellular basis of bone, biomaterial for osseous reconstruction, bone quality and quantity. It continues with data on oral implants, immediate and early implantation versus delayed implantation, immediate single tooth implant, ultra-short implant, zygomatic implants, all-on-four concept, autotransplantation, predictability, peri-implantitis and computer-guided implant dentistry. Information is presented regarding sinus elevation, conservative technique, options or alternatives, alveolar ridge splitting, vertical ridge augmentation, mandibular bone block graft, socket shield technique, canine impaction and fenestration and endodontic surgery combined with CAD/CAM technology. Among the reconstructive and plastic surgery techniques are mentioned: anterior and posterior iliac crest graft, SARPE and MARPE, nerve involvement, osseodensification, cleft lip and palate surgical intervention, orthognathic surgery, skull reconstruction for craniosynostosis and soft tissue plastic surgery.

Differential diagnosis in oral lesions, intraoral biopsy techniques, systemic diseases with oral manifestations, innovations in the management of temporomandibular joint disorders, medications used in oral surgery are topics covered at the end of this book.

The chapters comprehensively present the treatment procedures, being supported by eloquent images and tables.

The book "**Innovative Perspectives in Oral and Maxillofacial Surgery**" is addressed to undergraduate students in the field of dentistry, dental hygienists, general dentists, specialists and the elderly in maxillofacial surgery.

 [https://doi.org/10.25241/stomaedu.2022.9\(3-4\).bookreview.6](https://doi.org/10.25241/stomaedu.2022.9(3-4).bookreview.6)

The Books Review is drafted in the reviewer's sole wording and illustrates his opinions



Made by You

Dentsply Sirona CEE Central
Office & Showroom
Str. Vulturilor 98A, 030857, București
Tel.: 0774 074 094
office.romania@dentsplysirona.com
www.dentsplysirona.ro
<http://facebook.com/dentsplysirona.romania>

Open a world of confident smiles with Primescan's uniquely open approach to dentistry. Primescan as connected as your patients, now validated for any major lab software out there.



Scanned with Primescan

The **Stomatology Edu Journal** (*Stoma Edu J*) is one of the first **Green Open Access** journals in the field of dental medicine, publishing well-established authors, but equally committed to encouraging **early career researchers and professionals** alike to publish their work after a non-partisan, objective, double-blind rigorous peer-reviewed process. Our aim is to publish in the shortest possible time frame and ensure the rapid dissemination of your work via our journal page, but also through our indexing partners (**Dimensions, EBSCO, KUDOS, Google Scholar, Scilit**) which reach the vast mass of dental researchers, professionals and practitioners across the world. This journal fully adheres and complies to the policies and principles of the Committee on Publication Ethics (COPE).

1. Submission Instructions

The **Stomatology Edu Journal** (*Stoma Edu J*) publishes articles written only in English. All articles will be accompanied by the signed copyright form which can be returned by e-mail, fax (as scanned documents). All the responsibility for the originality of the material sent belongs to the author(s) alone. Each article will be evaluated by the peer-review committee composed of two independent peer-reviewers, in a blinded fashion, according to the peer-review protocol. All manuscripts must be original and exclusive. The Stomatology Edu Journal Editor will consider only articles that are original, have not been published elsewhere and have been submitted exclusively to the Stomatology Edu Journal. The manuscripts should be submitted online at www.ManuscriptManager.net/stom.

2. Ethics in publishing

The **Stomatology Edu Journal** (*Stoma Edu J*) and its editorial board fully adhere and comply to the policies and principles of Committee on Publication Ethics (COPE) (<https://publicationethics.org/files/2008CodeofConduct.pdf>). Your manuscript should not contain any information that has already been published. If you include already published figures or images, please obtain the necessary permission from the copyright holder to publish under the CC-BY license. Plagiarism, data fabrication and image manipulation are not tolerated. Plagiarism is not acceptable in the Stomatology Edu Journal (*Stoma Edu J*) submissions. Plagiarism includes copying text, ideas, images, or data from another source, even from your own publications, without giving any credit to the original source. Reuse of text that is copied from another source must be between quotes and the original source must be cited. If a study's design or the manuscript's structure or language has been inspired by previous works, these works must be explicitly cited.

If plagiarism is detected during the peer review process, the manuscript may be rejected. If plagiarism is detected after publication, we may publish a correction or retract the paper. Image files must not be manipulated or adjusted in any way that could lead to misinterpretation of the information provided by the original image. To verify the originality of content submitted to our journals, we use iThenticate (www.ithenticate.com) to check submissions against previous publications. All submitted manuscripts will be checked for any possible duplication or plagiarism with iThenticate (www.ithenticate.com). Nevertheless, corresponding authors are responsible for any fraud, intentional or unintentional malpractice.

3. Articles sent for publishing

The **Stomatology Edu Journal** (*Stoma Edu J*) publishes: original articles; reviews; case reports; technical procedures; consensus declaration coming from an association or from a group of specialists; letters to the editor. All articles must be up to 3,000 and 5,000 words for meta-analysis (the word count is for the manuscript text only). Letters to the editor must not exceed 400 words of text and have no more than 3 authors. Letters to the editor can be related to an article already published in the journal or it can represent original scientific contributions or events news/presentations etc. of interest for the reader.

4. Permissions and Ethics

For citations, tables, figures etc. which are not original, these must be accompanied by the written permission for their use and the full reference must be provided. Photographs of identifiable persons must be sent alongside the written permission of the person(s) and all regions that may allow the identification of the subject must be covered. The author must

have obtained, for all studies including human subjects, the permission of the subjects to be part of the study whilst keeping their anonymity. By sending the article, the author declares that he obtained this permission from all his subjects. All studies must respect the [Helsinki Declaration \(2013\)](#). For human and animal studies, the authors must have obtained the approval of the ethics committee from the University/Institute/etc. where the study was done. Consent for publication is required for studies involving human subjects - ALL case reports, letters that describe cases and some original articles. Cohort studies are exempt; instead evidence of IRB approval (name of IRB, date of approval and approval code/reference number) must be provided.

5. Manuscript preparation

The article must be written in conformity with the general recommendations of the International Committee of Medical Journal Editors.

<http://www.icmje.org/icmje-recommendations.pdf>

The **Stomatology Edu Journal** (*Stoma Edu J*) uses double-blind review, which means that both the reviewer and author name(s) are not allowed to be revealed to one another for a manuscript under review. The identities of the authors are concealed from the reviewers, and vice versa. To facilitate this, please include the following separately:

Title page (with author details): This should include the title, authors' names and affiliations, and a complete address for the corresponding author including an e-mail address, Author Contributions, Acknowledgements and Curriculum Vitae.

Blinded manuscript (no author details): The main body of the paper (including the references, figures, and tables) should not include any identifying information, such as the authors' names or affiliations. The articles must be sent either as a Microsoft Word 2000 document (*.doc) or as a Microsoft Word 2003/16/19 document (*.docx). The article will be written using Times New Roman font, size 12 for the characters with one and half (1 1/2) spaces between paragraphs. The manuscript must be sent in its final form. The pages will be numbered with the manuscript containing the following sections: title, authors, abstract, keywords, the text of article, contributions, acknowledgments, references, the figures and the tables legend.

A. The title of the manuscript will have a maximum of 100 characters without spaces, written in title case, centered capitals, and in 12 point bold Times New Roman font at the top of page. Abbreviations should be avoided within the title.

B. The author(s) will send their full name(s) and surname(s), the highest academic position, their full titles and their affiliations. All names are listed together and separated by commas. Provide exact and correct author names as these will be indexed in official archives. Affiliations should be keyed to the author's name with superscript numbers and be listed as follows: Laboratory, Department, Institute, Organization, City, State abbreviation (USA, Canada, Australia), and Country (without detailed address information such as city zip codes or street names).

The correspondent author will send his/her full name and surname, the highest academic position, his/her full title, his/her affiliation, his/her institution address, his/her telephone, fax and e-mail. The authors will send this information in the same format as that in the published articles.

C. The Structured Abstract

The abstract can have a maximum of 250 words. After the abstract, the author(s) must mention a maximum of 5 keywords. Keywords must be selected from **Medline Mesh**. Abbreviations are not accepted in the title or the abstract.

The abstract for Original Scientific Articles should be no more than 250 words using the following structure: Introduction; Methodology; Results; Conclusion.

The abstract for Review Articles should be no more than 250 words with the authors covering all the following information regarding the subject presented under the following subheadings: Background, Objective, Data Sources, Study Selection, Data Extraction, Data Synthesis.

The abstract for Case Reports should be no more than 250 words using the following structure: Aim, Summary and Key learning points: provide up to 5 short statements of the report.

The abstract for Clinical Articles should be no more than 250 words using the following structure: Aim, Methodology, Results and Conclusions.

D. The Article Text

Headings and Sub-headings

Except for special names (e.g. GABAergic), capitalize only the first letter of headings and subheadings. Headings and subheadings need to be defined in Times New Roman, 12, bold. You may insert up to 5 heading levels into your manuscript (not more than for example: 3.2.2.1.2 Heading title).

For original articles:

1. Introduction - a presentation of the most important aspects in the studied domain without doing a review of the literature. The purpose of this part is to present and backup the hypothesis on which the study was based.

2. Material and Methods - this section will include all required information so that the reader can verify the validity of the study including, but not limited to, subjects, measurements, statistics and ethics. The methods used should be discussed (why the methods have been chosen, which the limitations/advantages). A paragraph about the statistical analysis is required as well.

3. Results - the results of the study will be presented in a descending order of importance. An interpretation of the results will not be done in this section.

4. Discussion - the authors will present the way the results backup the original hypothesis, as well as the way in which the results are backed up or contradicted by the published literature. A paragraph must be dedicated to presenting the limitations of the study.

5. Conclusion - The conclusion presents the implications of this latest work. In addition, authors may consider discussing future plans or recommendations for future research etc. For all other types of articles, we recommend the use of a clear structure based on sections and sub-sections.

E. Author Contributions

The Author Contributions section is mandatory for all articles, including articles by sole authors. The Author Contributions statement must describe the contributions of individual authors and, in doing so, all authors agree to be accountable for the content of the work. Please list only 2 initials for each author, without periods, but separated by commas (e.g. AC, AS). In the case of two authors with the same initials, please use their middle initial to differentiate between them (e.g. AEC, ASC). Each author must be able to prove his active participation in the study by contributing to the concept, protocol, data gathering or analysis, their interpretation or by critically revising the manuscript.

F. Acknowledgments

Acknowledge persons who have made substantive contributions to the study. Specify grant or other financial support, citing the name of the supporting organization and grant number.

G. References

- The references will be written using the Vancouver style (<https://www.imperial.ac.uk/media/imperial-college/administration-and-support-services/library/public/vancouver.pdf>). All references that are identified with DOI (Digital Object Identifier) must be mentioned.

- For each reference use active links to the full text (DOI link), free PMC article, PubMed, Google Scholar, Scopus pages, and WoS were they exist:

- For all references identified with DOI the full-text link must be the CrossRef hyperlink

Examples

Articles with DOI

Singbartl G. Pre-operative autologous blood donation: clinical parameters and efficacy. *Blood Transfus.* 2011;9(1):10-18.

[CrossRef] [Free PMC Article] [PubMed] Google Scholar Scopus WoS

Articles without DOI

Mehta H, Shah S. Management of Buccal Gap and Resorption of Buccal Plate in Immediate Implant Placement: A Clinical Case Report. *J Int Oral Health.* 2015;7(Suppl 1):72-75.

[Full text links] [PubMed] Google Scholar

- The references will be numbered, in the order they appear in the text, in square brackets, as such: [3], [5,7-9].

- All sources found in the text must be present in the bibliography and all the papers mentioned in the bibliography must appear in the text.

- For references with more than 5 authors, list the first 3 authors followed by "et al."

- Full-page ranges should be given in expanded form (e.g., 426-429, not 426-9).

- If non-English-language titles are translated into English, bracketed indication of the original language should follow the title.

- All journals will be abbreviated and italicized names of journals according to the style in PubMed; refer to the National Library of Medicine (NLM) Journals Database (<http://www.ncbi.nlm.nih.gov/nlmcatalog/journals>) if needed. Journal names will be abbreviated according to the [List of Title Word Abbreviations](#)

- Information obtained from sources which are not published yet, but accepted for publishing will include at the end of the reference the mention "in print" between round parentheses.

- If the cited results have not been published yet the mention will be "personal communication" written in the text of article between round parentheses.

- Only references read by the authors of the article will be cited.

- An original article will have at most 50 references, a review will have at most 100 references, a letter to the editor 5 references, whilst all other types of articles will have the minimum number of references required.

6. Curriculum Vitae - Ultra Short version

Please provide a brief presentation of the first author and his contribution in the field, of maximum 130 words (with a 3.5x4.5 cm color photo).

7. Figures, Images, Tables

All illustrations must be numbered and cited in the text in order of appearance.

Figures and Images will be drawn professionally and sent in separate file(s) as jpeg, tiff or png files. Illustrations should preferably fill single column width (54 mm) after reduction, although in some cases 113 mm (double column) and 171 mm (full page) widths will be accepted. See the [Image quality specifications chart](#) for details. Image files also must be cropped as close to the actual image as possible.

In the text, each figure must be represented by a number, a title and a description. The authors will indicate where should the figure be placed in the text. All images or figures must come from the author's personal collection or the author must have rights to publish the image or figure. All images must be at or above [intended display size](#), with the following image resolutions: Line Art 800 dpi, Combination (Line Art + Halftone) 600 dpi, Halftone 300 dpi. We do not accept images or figures taken from the Internet.

The Tooth Identification System used in manuscripts must conform to the FDI International System. Units used in manuscripts must conform to the Système International d'Unités (SI).

Tables will be included in the text and each table will have a number and a short description if required.

8. Ownership Rights

By sending the article for publication the author(s):

- take full responsibility for the scientific content of the text and for the accuracy of the send data;

- become (co)author(s) of the manuscript (all further plagiarism accusation are addressed solely to the author(s) who signed the manuscript);

- declare they are the rightful owners of the images, figures and/or information sent for publishing and that they have the permission to publish all the materials for which they do not own the intellectual property rights;

- declare that the message/content of the manuscript is not influenced in anyway by commercial interests/previous engagements/ any sort of relations with other people or companies;

- transfer all rights for the manuscript to the Editorial Council for the *Stomatology Edu Journal* (*Stoma Edu J*).

9. Other

Previously mentioned limitations can be ignored in special cases with the agreement of the chief-editor and/or the publisher. All published materials cannot be returned.

Not taking into consideration the recommendations mentioned before can lead to delay in publishing the materials or may lead to not publishing the article.

The *Stomatology Edu Journal* (*Stoma Edu J*) also helps authors measure the impact of their research through specialist partnerships with Kudos and Altmetric.

SUBSCRIPTION



I want to subscribe to



- 1 year Subscription (4 issues of the journal) - 280 RON (72 Euro for foreign subscribers)
- 2 years Subscription (8 issues of the journal) - 540 RON (136 Euro for foreign subscribers)
- Single Issue - 80 RON (20 Euro for foreign subscribers)

Please send the filled subscription at the following e-mail: roposturo@gmail.com.

PLEASE COMPLETE ALL THE SUBSCRIPTION FIELDS IN CAPITAL LETTERS!

Name..... Surname

Mrs. Mr. Ms.

Home Address

City..... Sector..... District.....

Post office code..... Mobile phone.....

E-mail:..... Web.....

Student Resident Specialist doctor Primary doctor

Competence.....

Institution.....

Activity domain: Private Public

Department..... Position.....

Specialty..... Institution address.....

City..... Sector..... District.....

Post office code..... Phone.....

E-mail:..... Web.....

CUI (Institution Unique Registration Code)

VAT Payer: Yes No

Invoice - please fill all the necessary details for invoice:

Name..... CNP (Personal Identification Number).....

Or

Institution CUI (Institution Unique Registration Code).....

Date.....

Signature.....

After filling the subscription, please send it together with the proof of payment to:

ROPOSTURO

Romanian Association of Oral Rehabilitation and Posturotherapy

10, Ionel Perlea St., 1st District, RO-010209 Bucharest, Romania

Tel: +4021 314 1062, Fax: +4021 312 1357

e-mail: roposturo@gmail.com

www.roposturo.ro

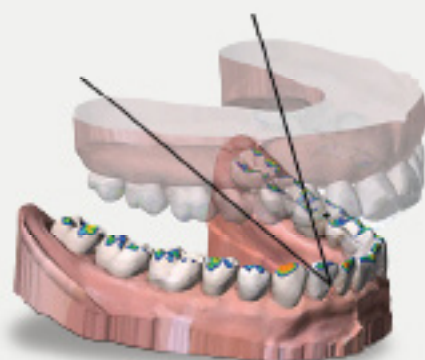
The New Dimension in Jaw Movement Analysis

zebris

JMA *Optic*

Welcome to the World of Functional Digital Dentistry

- Planning and preparation of dental restorations and dental splints under functional aspects



Digital function and occlusion analysis
Programming of articulators



The digital workflow with exocad
Export of all relevant position and movement data

FDI 2022, Mumbai, India

World Dental Congress

September 29 - October 2

Reunite & Rebuild Dentistry in the City of Dreams



LIGHTS, CAMERA
BOLLYWOOD

